

The Ophthalmologic Management of Acute Stevens-Johnson Syndrome

DARREN G. GREGORY, MD

ABSTRACT Stevens-Johnson syndrome (SJS) and its more severe variant, toxic epidermal necrolysis (TEN), cause significant ocular surface damage. The majority of affected patients develop conjunctival inflammation during the acute phase of the disease. If intense, this inflammation yields permanent destruction of the normal mucosal tissue of the ocular surface and eyelids. Loss of the normal glandular structures leads to severe dry eye problems and vision loss. Medical treatments do little to arrest these problems, and repairing the damage after the acute phase is difficult, if not impossible. Recently, the application of cryopreserved amniotic membrane to the ocular surface during the acute phase of the disease has shown great promise in limiting the destructive inflammation and its long-term sequelae. A rationale for this treatment and a detailed description of the application procedure are provided, along with practical guidelines for the managing surgeon.

KEY WORDS amniotic membrane, conjunctivitis, dry eye, inflammation, Stevens-Johnson syndrome, symblepharon, toxic epidermal necrolysis

Accepted for publication February 2008.

From the Rocky Mountain Lions Eye Institute, University of Colorado School of Medicine, Denver, Colorado, USA.

The author has no proprietary or commercial interest in any concept or product discussed in this article.

Single-copy reprint requests to: Darren G. Gregory, MD (address below).

Corresponding author: Darren G. Gregory, MD, Rocky Mountain Lions Eye Institute, 1675 North Ursula Street, P.O. Box 6510, Mail Stop F731, Aurora, CO 80045-0510. Tel: (720) 848-2500. Fax: (720) 848-5014. Email: darren.gregory@uchsc.edu.

©2008 Ethis Communications, Inc. *The Ocular Surface* ISSN: 1542-0124. Gregory DG. The ophthalmologic management of acute Stevens-Johnson syndrome. 2008;6(2):87-95.

I. INTRODUCTION

Stevens-Johnson syndrome (SJS) is a rare, acute, exfoliative disease involving the skin and mucous membranes. The incidence of SJS is approximately six cases per million persons per year.^{1,2} It is most commonly drug-induced, and it produces a clinical picture similar to that of an extensive partial-thickness skin burn. Its effects on the ocular surface can be devastating, leaving survivors with permanent, severe dry eye problems and debilitating photophobia. The most severe form of the syndrome, toxic epidermal necrolysis (TEN), involves over 30% of the body surface and can be life-threatening. TEN is less common than SJS, with an incidence of approximately 1-2 cases per million persons per year.^{1,2}

This article will review the ocular manifestations of SJS and TEN and discuss current management approaches based on published literature and the author's extensive personal experience managing such patients at both a regional burn center and a large children's hospital.

II. PATHOPHYSIOLOGY

A. Pathophysiology in the Epidermis

The current understanding of the pathophysiology of SJS/TEN involves massive apoptosis of keratinocytes within the epidermis³ (not to be confused with "keratocytes" of the cornea). It seems that intermediate drug metabolites can initiate an immune response in susceptible individuals. This yields an increase in release of Fas-ligand, a type II transmembrane protein that belongs to the tumor necrosis factor (TNF) family, from peripheral blood mononuclear cells. Elevated Fas-ligand levels are detectable in the serum of SJS/TEN patients.⁴ This ligand binds to and activates Fas, which is a keratinocyte cell surface receptor that initiates apoptosis.^{4,5}

Other factors, such as genetic susceptibility⁶ and low N-acetylating capacity,⁷ may be contributory. Cytotoxic T lymphocytes⁸ and multiple cytokines⁹ also seem to have a significant role in the process. Whatever the mechanism, however, the end result is widespread apoptosis within the epidermis that leads to a blistering or "scalded-skin" appearance.

B. Acute Ophthalmic Pathology

A significant majority of patients with SJS/TEN will have

OUTLINE

- I. Introduction
- II. Pathophysiology
 - A. Pathophysiology in the epidermis
 - B. Acute ophthalmic pathology
- III. Medical management
 - A. Systemic care
 - B. Nonsurgical ophthalmologic management
 - 1. Topical medications
 - 2. Symblepharon rings
- IV. Surgical management with use of amniotic membrane
 - A. Background
 - B. Surgical technique
 - 1. General considerations
 - 2. Indications for amniotic membrane use
 - 3. Surgical technique
 - a. Eyelids
 - b. Ocular surface
 - c. Alternative surgical options
 - 4. Postoperative care
- V. Conclusions

ophthalmic pathology.¹⁰⁻¹⁴ In large retrospective studies, Power et al¹⁰ and Chang et al¹¹ reported ocular involvement in 69% and 81%, respectively, of patients with SJS, and in 50% and 67%, respectively, of those with TEN. Yip et al reported acute ocular involvement in 69% of SJS/TEN patients.¹³ Damage to the ocular surface appears to be caused by apoptosis and necrosis in the epidermal layers, as well as the intense inflammation that can follow. The ophthalmic pathology mainly involves the conjunctiva, both bulbar and palpebral, but it can also involve the cornea, lid margins, eyelashes, and eyelid skin.

Mild cases are manifested by a conjunctivitis, which can produce localized conjunctival epithelial defects. Ocular discomfort and photophobia tend to be minimal in such cases. Severe cases yield a diffuse, destructive inflammation with pseudomembranous and membranous conjunctivitis. Discomfort and photophobia tend to be more pronounced in this situation. The raw surfaces can lead to adhesion formation between the palpebral and bulbar conjunctiva, known as symblepharon. The intense inflammation can destroy goblet cells and accessory lacrimal glands, as well as the secretory ductules of the main lacrimal gland.¹¹ The normal mucosal structure of the conjunctiva is eventually replaced by a cicatricial epithelium and subconjunctival scar tissue.¹³

The eyelids themselves can also suffer significant damage. Contracture of the palpebral conjunctiva can yield cicatricial entropion. Lid margin inflammation can cause widespread destruction of meibomian gland orifices and the glands themselves.¹³ Eyelash architecture can also be affected, resulting in trichiasis and distichiasis. The

abnormally directed lashes can abrade the compromised ocular surface and lead to discomfort, corneal abrasions, and corneal ulceration. Keratinization of the lid margins and palpebral conjunctiva further contributes to discomfort and corneal damage via blink-related microtrauma to the corneal epithelium.¹³

Destruction of the corneal limbal stem cells is perhaps the most dire consequence of the aforementioned pathologies and can lead to vascularization and thickening of the corneal epithelium.¹² This “conjunctivalization” of the cornea, accompanied by the abnormal tear film, produces severe visual loss. Additionally, it creates a poor prognosis for any future corneal transplantation.

Interventions during the acute phase are crucial, as the long-term sequelae can be difficult, if not impossible, to repair. The visual disability that occurs is particularly cruel, in that it is accompanied by severe, chronic pain and photophobia.

III. MEDICAL MANAGEMENT**A. Systemic Care**

The acute systemic complications of SJS/TEN are due to the widespread loss of skin and mucous membranes, as also occurs in burn victims. Sepsis and pneumonia can be life-threatening, with mortality rates approaching 40% in some series.¹⁴ Early referral to a facility experienced in the care of burn patients significantly decreases mortality rates.¹⁵⁻¹⁹ It is important for the ophthalmologist to educate the appropriate staff in these facilities regarding the need for immediate ophthalmologic evaluation of all SJS/TEN patients.

Supportive care is the only systemic intervention with proven benefit on mortality. The use of systemic corticosteroids and intravenous immunoglobulin (**IVIG**) has had varying results and remains controversial.^{5,10,12,20-22} Schneck et al retrospectively reviewed data from patients in France and Germany who were enrolled in EuroSCAR, a case-control study of mortality risk factors in SJS/TEN patients. They found that neither IVIG nor corticosteroids showed any significant effect on mortality as compared to supportive care only, although they did suggest that the use of corticosteroids merited further study.²² On the other hand, French reviewed nine non-controlled clinical studies that analyzed the therapeutic effect of IVIG in TEN.⁵ Although acknowledging limitations of the studies, he reported that seven of the nine studies suggested a benefit of IVIG on mortality.

Multiple case reports and one small case series suggest a potential benefit of systemic cyclosporine in the treatment of acute TEN, but no good comparative clinical trial data exists.²³⁻²⁵ No prospective, randomized controlled studies for any of these systemic treatments currently exist.

B. Nonsurgical Ophthalmologic Management**1. Topical Medications**

The ophthalmologic management of acute SJS/TEN should focus on infection prophylaxis, adhesion prevention, and minimization of destructive inflammation. Topical

medications have no proven benefit in this regard, as there are no published studies or even case reports examining such treatments. In the absence of literature-based guidance, the ophthalmologist must still devise a course of treatment. Ophthalmic hygiene makes sense and probably does no harm. Vigorously rinsing the eyes each day with sterile saline removes any inflammatory debris from the ocular surface and lid margins and may help to decrease the risk of ocular surface infection.

The judicious use of prophylactic topical antibiotics also seems warranted. I use moxifloxacin 0.5% (Vigamox[®], Alcon, Fort Worth, TX) for this purpose because it is bactericidal, is effective against most common skin pathogens, achieves high corneal concentrations, and a single drop maintains high tear film concentrations for at least 6 hours following application.²⁶ Additionally, 20 minutes following application, a single dose of moxifloxacin produces conjunctival drug concentrations 6-14 times higher than other fluoroquinolone drops.²⁷ These factors should allow effective infection prophylaxis with a minimum of drop applications.

Systemic corticosteroids and cyclosporine have shown some potential as treatments for SJS/TEN, although their use remains controversial. Systemic corticosteroids do not seem to decrease ocular inflammation,¹⁰ but topical application of corticosteroid has not been studied. The use of topical cyclosporine has been suggested as a possible means of decreasing the intensity of ocular surface inflammation in SJS/TEN, but no studies of this treatment currently exist.²⁸

My routine is to use moxifloxacin 0.5%, cyclosporine 0.5% (Restasis[®], Allergan, Irvine, CA), and dexamethasone 0.1% drops each twice per day. The drops are applied sequentially 2 hours apart in the morning and then again in the evening. A third drop of moxifloxacin may also be applied at midday, as the recommended dose for treatment of bacterial conjunctivitis is three times daily. Combination tobramycin/dexamethasone ointment (Tobradex[®], Alcon, Fort Worth, TX) is applied to the eyelid margins and eyelashes at night. It is important to educate the nursing staff in the proper application of the medications. I have used this combination of topical antibiotic and antiinflammatory medications in dozens of SJS/TEN patients over the past few years with no infectious complications. The goal has been to strike a balance between theoretical benefit and possible harm from overmedicating an already fragile ocular surface.

2. Symblepharon Rings

Symblepharon can form even when the measures described above are taken. Daily inspection of the fornices must be performed by an ophthalmologist. Following the application of topical anesthetic, the fornices are swept by a round-tipped muscle hook or scleral depressor to assess for early symblepharon formation. Symblepharon rings are very effective in preventing symblepharon. I prefer oval-shaped rings that are essentially a lucite conformer (Jardon Eye Prosthetics, USA) with a round window cut out over the cornea. They fill the fornices well and provide good

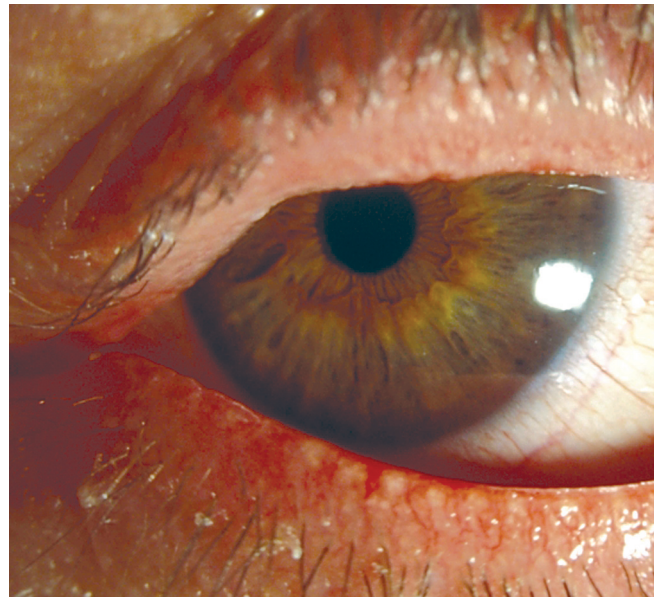


Figure 1. Severe lid margin keratinization and dry eye 4 months after TEN with severe ocular involvement. The eyes had been treated medically during the acute phase, without amniotic membrane grafting.

separation of the palpebral conjunctiva from the bulbar conjunctiva. The rings come in a variety of sizes, and I choose the largest that will allow eyelid closure. The superior fornix has more volume, and it is easiest to insert the superior portion first and then tuck the inferior edge under the lower eyelid. In children, sedation may be necessary for the initial placement, but in my experience, the rings are well tolerated once in place.

Although the above measures can successfully prevent symblepharon and infection, they do little to prevent the destruction of the normal mucosal structures of the bulbar and palpebral conjunctiva. I have used these treatments on multiple SJS/TEN patients with severe ocular involvement, and they were still left with severe lid margin damage and permanent debilitating dry eye disease with photophobia (Figure 1). These patients eventually had most of their symptoms alleviated by Boston Scleral Lenses (Boston Foundation for Sight, Boston, MA),²⁹ but they are completely dependent on the lenses for the rest of their lives, and the use of the lenses can be challenging in a child. These facts have prompted the search for more definitive and effective therapies during the acute phase of the disease.

IV. SURGICAL MANAGEMENT WITH USE OF AMNIOTIC MEMBRANE

A. Background

Recently, a number of case reports have described the use of cryopreserved amniotic membrane to minimize the destructive inflammation during the acute phase of SJS/TEN.^{15,30-33} A brief summary of the major findings in these reports is shown in Table 1. Amniotic membrane is the innermost layer of the fetal membranes arising from the placenta. It consists of a single layer of epithelial cells attached to a thick basement membrane and an avascular

Table 1. Summary of Literature Reports of Amniotic Membrane Transplant for Acute SJS/TEN

Reference	John, 2002 ³⁰	John, 2002 ³⁰	Di Pascuale, 2005 ¹⁵	Kobayashi, 2006 ³¹	Muqit, 2007 ³²	Tandon, 2007 ³³
Case Number	1	2	3	4	5	6
Age (years)	6	8	4	6	10	12
Gender	Male	Female	Male	Male	Female	Female
Diagnosis	TEN	TEN	SJS	TEN	SJS	TEN
Preoperative Findings						
Lid						
Margin inflammation	Yes (OU)	Yes (OU)	Yes (OU)	Yes (OU)	No	Yes (OU)
Early symblepharon	Yes (OU)	Yes (OU)	NA	Yes (OU)	Yes (OU)	Yes (OU)
Conjunctiva						
Inflammation	Yes (OU)	Yes (OU)	Yes (OU)	Yes (OU)	Yes (OU)	Yes (OU)
Tarsal/fornix ulceration	NA	NA	Yes (OU)	Yes (OU)	Yes (OU)	Yes (OU)
Cornea						
Epithelial defect	No	Total (OU)	No	Total (OD), Partial (OS)	Partial (OU)	No
Limbal involvement	No	No	No	Yes (OS)	No	No
Treatment						
Timing of AMT (days)*	<14	<14	7	5	3	3
Location of AMT						
Lid margin	Yes	No	Yes	Yes	Yes	Yes
Tarsal conjunctiva	Yes	Yes	Yes	Yes	Yes	Yes
Ocular surface	Yes	Yes	Yes	Yes	Yes	Yes
Outcome						
Follow up (months postoperative)	36	34	12	4	6	3
Persistent conjunctival inflammation	No	No	No	No	No	No
Cicatricial complications						
Lid margin	No	No	Mild (OU)	No	No	Mild (OU)
Tarsal conjunctiva	No	Mild (OU)	Mild (OU)	Mild (OD)	No	Mild (OU)
Symblepharon	No	No	No	Focal (OD)	No	Focal (OD)
Limbal stem cell deficiency	No	No	No	No	No	No
Dry eye	No	Mild	No	No	No	No
Photophobia	NA	Mild	No	NA	No	NA
Other morbidity	No	Madarosis (OU)	No	No	Trichiasis (OU)	Trichiasis (OU)
BCVA	20/20	20/30 (OD), 20/40 (OS)	NA	20/16	20/16	20/20

Abbreviations: AMT, amniotic membrane transplantation; NA, not available; OD, right eye; OS, left eye; OU, both eyes; PEE, punctate epithelial erosions; SJS, Stevens-Johnson syndrome; TEN, toxic epidermal necrolysis; BCVA, best-corrected visual acuity.

*After onset of eye symptoms.

stroma.³⁴ Although the exact mechanism remains unknown, amniotic membrane exhibits potent antiinflammatory and antiscarring effects.^{35,36} It has been successfully used in a variety of settings, such as acute chemical burns^{37,38} and corneal ulceration,^{39,40} to decrease inflammation and promote epithelial healing.⁴¹

I began using cryopreserved amniotic membrane (Amniograft®, Bio-Tissue Inc., Miami, FL) in the management of acute SJS/TEN in early 2006. Prior to that, I had managed a number of severe cases using the medical therapies described in Section III, and it was clear that they were inadequate. The subsequent use of amniotic membrane during the acute phase of SJS/TEN has prevented all of the most serious ocular sequelae in six consecutive patients

with severe ocular involvement (a detailed analysis of this case series is in preparation). These results, combined with the growing number of individual case reports on the subject, provide an increasingly compelling argument for the use of amniotic membrane in cases of SJS/TEN with intense conjunctival inflammation.

B. Surgical Technique

1. General Considerations

Whenever possible, amniotic membrane should be applied under an operating microscope in an operating room. In cases with extensive skin involvement, the patients are often taken to surgery for skin debridement and dressing changes. It is rare for the medical situation, itself, to pro-

hibit the ophthalmic procedures from being done in the operating room as well. The procedure I will describe is time-consuming, however, and can certainly be performed in separate stages for logistical purposes.

If a trip to the operating room is impossible, the procedure can be performed at the bedside, but it is technically more difficult. The eyelid portions of the surgery can be done with loupes, and Prokera® (Bio-Tissue, Miami) can be used to cover the ocular surface. Prokera® consists of a polycarbonate ring-set with a sheet of amniotic membrane clipped in between and stretched across the lumen of the ring. The combination is placed on the eye like a contact lens, with the ring over the perilimbal conjunctiva and the amniotic membrane stretching across the cornea. The ring has some of the effect of a symblepharon ring, but does not extend as far into the fornices. The membrane does not cover the ocular surface beyond the cornea and perilimbal conjunctiva. Although Prokera® is convenient to use, whenever possible I prefer the increased conjunctival coverage provided by a sheet of amniotic membrane fixated to the ocular surface with sutures and a full symblepharon ring.

No matter how the procedure is performed, early intervention will help decrease the risk of damage to the ocular surface. The cryopreserved amniotic membrane can be overnight-shipped in North America. If the procedures are performed with some frequency, however, having it in stock at the hospital helps avoid delay in treatment. It can be stored in a "bone freezer" (-80° C) for up to 12 months.

Finally, the interaction with the patients and their loved ones deserves mention. These patients are frequently completely healthy prior to the onset of SJS/TEN. Within a few days of the illness, they may suddenly be critically ill. With extensive skin loss, bloody discharge from the mouth, and a variety of machines and tubes providing systemic support, their appearance can be quite distressing. Loved ones may be understandably panicked, particularly if they have read the wealth of available internet information on the Stevens-Johnson syndrome.

Because of the relative urgency of the ophthalmic situation, the ophthalmologist may advise the use of amniotic membrane at the first meeting with the patient. In pediatric patients or patients on heavy sedation or a ventilator, consent for treatment may be the responsibility of family members. Proposing to cut off all the eyelashes, cover the eyes and eyelids with placental tissue, and then place a large plastic ring over both eyes can be an alarming prospect. The ophthalmologist must be prepared to spend time addressing the many questions and concerns that inevitably arise. The published case reports detailing the successful use of amniotic membrane in this setting are an invaluable resource to help educate the patient, or family. The family also finds it reassuring that the cryopreserved amniotic membrane is an FDA-approved product, and not something "experimental." Lastly, it is important at the outset to alert the patient and the family that the procedure may need to be performed multiple times over the ensuing weeks if the inflammation remains severe and persistent.

2. Indications for Amniotic Membrane Use

Not all SJS/TEN patients with ocular involvement will develop serious sequelae.^{10,11} Patients with signs of intense or worsening inflammation of the conjunctiva and lid margins should certainly be considered for treatment with amniotic membrane transplantation. Findings in this regard are membranous conjunctivitis, early symblepharon formation, and intense lid margin inflammation with lash loss (Figure 2). Any of these suggest an intensity of destructive inflammation that puts the patient at a high risk for ocular surface scarring and severe dry eye problems. If able to communicate, these patients tend to describe significant ocular discomfort and photophobia. Extensive corneal epithelial defects are also of concern, but they may be partly related to exposure keratopathy, if the patient is sedated and on a ventilator.

Patients with moderate, nonmembranous conjunctivitis and minimal lid margin involvement need close daily monitoring with careful inspection of the fornices and tarsal conjunctiva for hidden inflammation or symblepharon. The described medical treatments should be implemented. Localized conjunctival epithelial defects are common in these patients and should be measured each day with use of fluorescein staining (Figure 3). Most digital cameras allow detailed bedside photographs of the defects to help document any changes. Handheld direct ophthalmoscopes are helpful for highlighting the fluorescein stain and for illuminating the eye for photos. Any signs of progressively worsening inflammation or expanding epithelial defects should warrant consideration for treatment with amniotic membrane.

In the two years since I began using amniotic membrane to treat SJS/TEN, I have cared for over a dozen SJS/TEN patients with ocular involvement. Approximately half of them have been treated with amniotic membrane transplantation. Those patients not treated with amniotic membrane had mild, nonprogressive ocular involvement and were managed medically. All have recovered without scarring sequelae or dry eye symptoms. Considering the dire consequences of severe cases, however, and knowing that some cases are in the "middle ground," I would always opt to use amniotic membrane treatment, if there is concern. The window of opportunity to effectively prevent the potentially serious, permanent problems begins to close within 2-3 weeks of the onset of symptoms.

3. Surgical Technique

a. Eyelids

Amniotic membrane transplantation as a surgical treatment for acute SJS/TEN was first described by John et al, in 2002.³⁰ The techniques I use are modifications of those described by Kobayashi et al in 2006.³¹ A skilled assistant is helpful, as many of the described steps require three hands. Traction sutures, however, can be used to place the eye in the necessary positions if a surgical assistant is unavailable.

For the eyelids, I cut a 3.5 cm square of the amniotic membrane in half, using one half for the upper lid and one half for the lower. The membrane comes attached to white

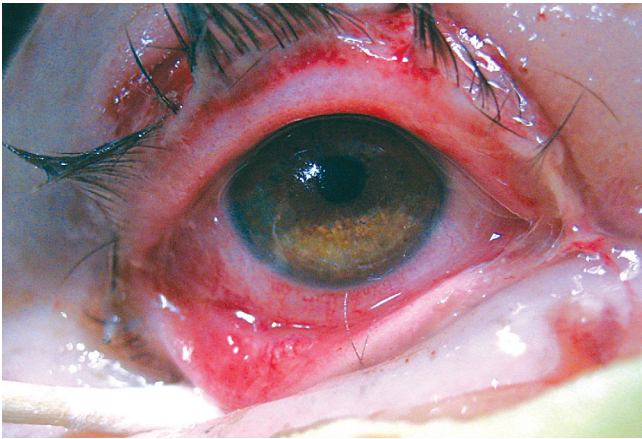


Figure 2. Acute TEN with intense inflammation of the bulbar conjunctiva, palpebral conjunctiva and lid margins.

nitrocellulose filter paper and can be lifted loose, using nontoothed forceps, starting at the corners. I loosen the entire sheet from the paper, but do not actually remove it from the paper until the moment I apply it to the skin or eye. The sticky stromal side of the membrane is against the paper. A cellulose sponge will stick to the stromal side, but not the basement membrane side. This can help determine the membrane's orientation should it become confused during the procedure.

General anesthesia is used for procedures performed in the operating room. If done at the bedside, intravenous sedation and analgesia can be used to augment anesthesia applied to the eyelids and ocular surface. Prior to the placement of amniotic membrane, the skin and eye are rinsed with sterile saline, and quinolone antibiotic drops are applied to the ocular surface. Given the inflamed state of the skin and ocular surface, a full iodine surgical prep is generally not employed. The eyelashes are trimmed down to the skin with Vannas scissors, and debris or necrotic tissue is removed from the lid margin. Any symblepharon is also lysed.

The amniotic membrane is then slid onto the eyelid skin, with the stromal side in contact with the skin surface.

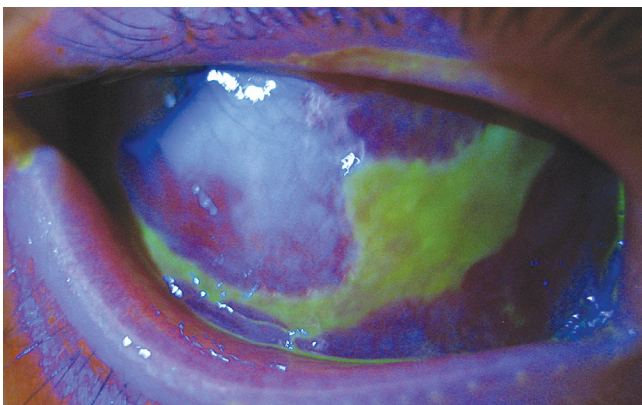


Figure 3. Acute SJS with mild/moderate ocular involvement. Photo shows subconjunctival hemorrhage and a localized, nonprogressive epithelial defect of the left temporal conjunctiva (patient is looking to his right).

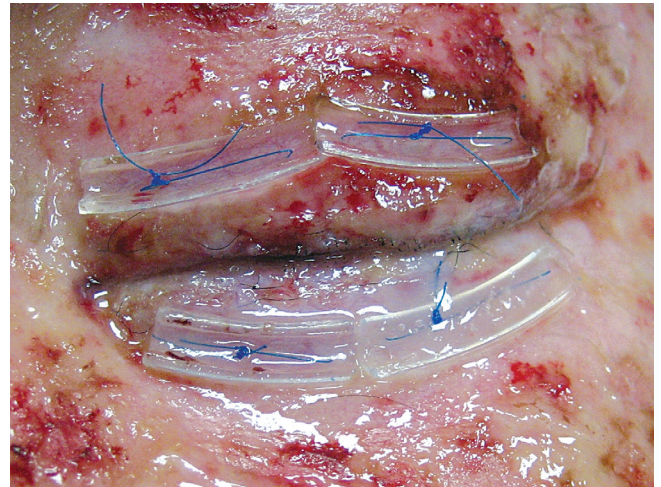


Figure 4. Immediate postoperative appearance following application of amniotic membrane to lid margins and palpebral conjunctiva. Full-thickness polypropylene sutures and soft plastic bolsters are visible on both eyelids.

It is positioned so that one of the long edges of the membrane covers the lid margin and 1-2 mm of the adjacent skin beyond the lashes. This edge is fixated along the lid skin with a running 8-0 nylon suture. The loose edge at the opposite end of the membrane sheet is then tucked down into the fornix of that eyelid with muscle hooks. A double-armed 6-0 polypropylene suture is passed full-thickness through the membrane as deep in the fornix as possible and then out through the eyelid skin. The twin passes should be about 1 cm apart and are tied over a bolster (I use cut intravenous tubing for bolsters). Two sets of these sutures are used per eyelid, one nasally and one temporally (Figure 4). This same procedure is then performed on the remaining eyelids.

I favor the use of nonabsorbable sutures, despite the need for later removal. The goal of the surgery is to minimize any inflammation, and nonabsorbable sutures are less likely to stimulate an inflammatory response. In adults, suture removal can be done with anesthetic drops and gel. An operating microscope is helpful for visualizing the ocular surface sutures. In young children, an examination under anesthesia may be required for suture removal, as well as adequate evaluation of the conjunctival surfaces.

b. Ocular Surface

For the ocular surface, a full 3.5 cm² piece of amniotic membrane is used on each eye. I mark the center point of the membrane sheet with a surgical marking pen prior to removal from the filter paper. The mark helps keep it centered over the ocular surface during placement and suturing. A few drops of lidocaine with epinephrine are applied to the conjunctiva to decrease bleeding. The membrane is then sutured to the conjunctiva with a 10-0 nylon running suture in a purse string fashion with suture bites placed approximately 2 mm posterior to the limbus. Bleeding under the membrane can make it difficult to pass the needle through membrane and the underlying conjunctiva.

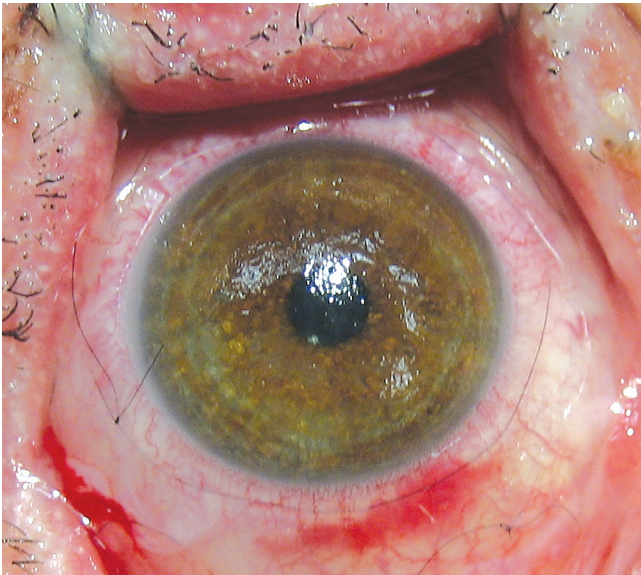


Figure 5. A 10-0 nylon running suture is visible in the perilimbal conjunctiva 12 days following the application of amniotic membrane to the ocular surface.

The membrane can be lifted and blood rinsed away with balanced salt solution, if needed. The suture tails on the knot are left 4-5 mm long so they will lie flat on the ocular surface (Figure 5).

A muscle hook is then inserted into the superonasal fornix to rotate the eye in that direction. A single, interrupted 10-0 nylon suture is used to fixate the membrane to the conjunctiva as far down in the inferotemporal fornix as possible. A similar procedure is used to place similar sutures in the 3 remaining quadrants. Sutures can also be placed through membrane and conjunctiva at the medial and lateral canthi. It is important to document the location of the interrupted sutures so they can all be found at the time of suture removal. I do not cut out the portion of amniotic membrane covering the cornea, even though it will obscure the vision. The vision is equally blurred in both eyes, and the blur is temporary, as the corneal portion of

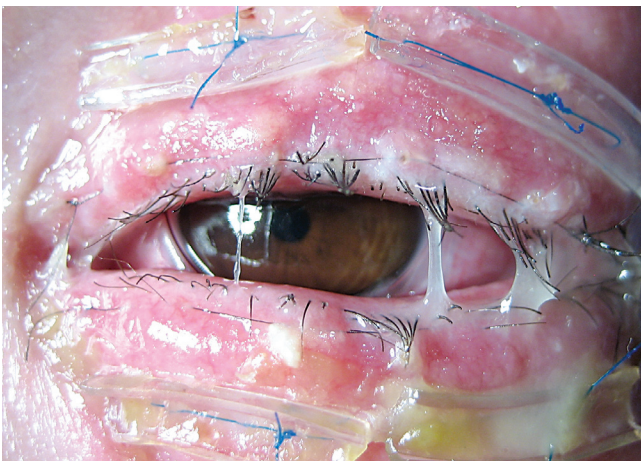


Figure 6. Postoperative appearance 10 days following application of amniotic membrane to eyes and eyelids. Degrading membranes take on a mucopurulent appearance. No infection was present.

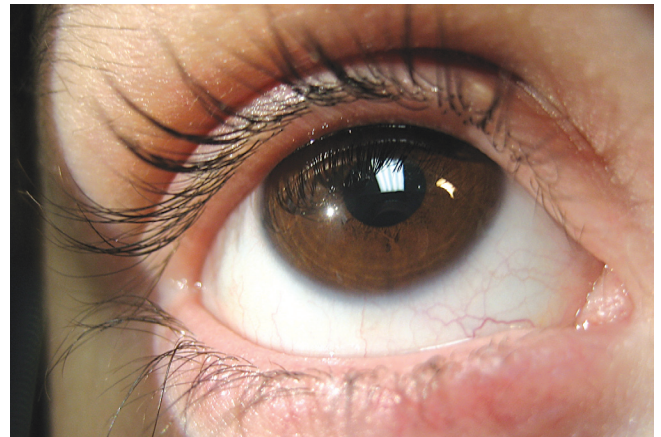


Figure 7. Same patient as shown in Figures 4 and 6, now 4 months after the episode of TEN treated with amniotic membrane grafting. Patient has no dry eye problems or other significant sequelae.

the membrane tends to degrade over 5-7 days. Amblyopia has not been a problem in the young children treated in this fashion, and the membranes have been well tolerated.

Once all the membranes are in place, a symblepharon ring is placed on the eye. The ring serves many purposes beyond the prevention of symblepharon. It decreases cicatricial foreshortening of the fornices and helps keep the membranes well apposed to the conjunctival surfaces of both the eye and eyelids. Under the effects of general anesthesia, there may be mild lagophthalmos with the rings in place, but closure quickly improves once the anesthesia wears off.

c. Alternative Surgical Options

Although the most secure adhesion of the amniotic membrane to the ocular surface is obtained by use of sutures, alternative application techniques have been described using biologic adhesive. Fibrin tissue adhesive (TISSEEL, Baxter, Deerfield, Illinois) consists of a two-component fibrin biomatrix that offers highly concentrated human fibrinogen to seal tissue and is sufficient to adhere the amniotic membrane to the ocular surface.⁴²⁻⁴⁵ Application of adhesive is more rapid than placement of sutures and can be done at the bedside with loupes to achieve short-term adhesion, albeit not as secure as with suture placement.

4. Postoperative Care

Following amniotic membrane placement, the described medical treatments of the eye are resumed. Daily examinations are performed. The membrane degrades over 10-14 days, with the lid margin and corneal portions breaking down first. The skin lesions are often beginning to improve at this point, but the mucosal inflammation involving the mouth and eyes frequently persists weeks longer than the skin lesions. Patients may be discharged home with membranes and symblepharon rings in place, assuming that frequent outpatient follow-up checks and adequate outpatient support are possible.

As the membranes degrade, they can resemble mucopurulent discharge and arouse concern about superinfection

(Figure 6). Loose areas can be trimmed away and careful inspection for any corneal infiltrates should be performed with each examination. At 10-14 days after the placement of the membranes, the sutures are removed. Any areas that remain significantly inflamed are retreated. Special priority is given to the lid margins and tarsal conjunctiva, as scarring of these structures is particularly associated with long-term ocular morbidity.¹⁵ I have had patients who required up to three separate applications of amniotic membrane over the course of a month due to persistent severe conjunctival inflammation.

V. CONCLUSIONS

Along with chemical burns and cicatricial pemphigoid, SJS/TEN has long been one of the worst diseases to affect the ocular surface. Medical treatments during the acute phase do not effectively prevent the serious problems of severe dry eye and photophobia. Late attempts to repair the long-term cicatricial sequelae are difficult and prone to failure. Although the use of scleral contact lenses may allow rehabilitation of the damaged ocular surface and a decrease in symptoms for these patients, prevention of the scarring and sequelae of the acute inflammation is preferable. Recently, the application of cryopreserved amniotic membrane to the eyes and eyelids during the acute phase of the disease has shown great promise as a means of preventing both the cicatricial sequelae and the dry eye problems (Figure 7). The care of SJS/TEN patients during the acute phase is labor-intensive, but the investment of time and effort at this stage can help them avoid a lifetime of eye-related misery. Seeing these patients resume a normal life, free from significant eye pain or problems, is immensely rewarding for the ophthalmologist.

REFERENCES

- Roujeau JC, Guillaume JC, Fabre JP, et al. Toxic epidermal necrolysis (Lyell syndrome). Incidence and drug etiology in France, 1981-1985. *Arch Dermatol* 1990;126:37-42
- Roujeau JC, Kelly JP, Naldi L, et al. Medication use and the risk of Stevens-Johnson syndrome or toxic epidermal necrolysis. *N Engl J Med* 1995;333:1600-7
- Paul C, Wolkenstein P, Adle H, et al. Apoptosis as a mechanism of keratinocyte death in toxic epidermal necrolysis. *Br J Dermatol* 1996;134:710-4
- Abe R, Shimizu T, Shibaki A, et al. Toxic epidermal necrolysis and Stevens-Johnson syndrome are induced by soluble Fas ligand. *Am J Pathol* 2003;162:1515-20
- French LE. Toxic epidermal necrolysis and Stevens Johnson syndrome: our current understanding. *Allergol Int* 2006;55:9-16
- Roujeau JC, Huynh TN, Bracq C, et al. Genetic susceptibility to toxic epidermal necrolysis. *Arch Dermatol* 1987;123:1171-3
- Dietrich A, Kawakubo Y, Rzany B, et al. Low N-acetylating capacity in patients with Stevens-Johnson syndrome and toxic epidermal necrolysis. *Exp Dermatol* 1995;4:313-6
- Nassif A, Bensussan A, Dorothee G, et al. Drug specific cytotoxic T-cells in the skin lesions of a patient with toxic epidermal necrolysis. *J Invest Dermatol* 2002;118:728-33

- Nassif A, Moslehi H, Le Gouvello S, et al. Evaluation of the potential role of cytokines in toxic epidermal necrolysis. *J Invest Dermatol* 2004;123:850-55
- Power WJ, Ghorraishi M, Merayo-Llloves J, et al. Analysis of the acute ophthalmic manifestations of the erythema multiforme/Stevens-Johnson syndrome/toxic epidermal necrolysis disease spectrum. *Ophthalmology* 1995;102:1669-76
- Chang Y, Huang F, Tseng S, et al. Erythema multiforme, Stevens-Johnson syndrome, and toxic epidermal necrolysis: acute ocular manifestations, causes, and management. *Cornea* 2007;26:123-9
- De Rojas MV, Dart JK, Saw VP. The natural history of Stevens-Johnson syndrome: patterns of chronic ocular disease and the role systemic immunosuppressive therapy. *Br J Ophthalmol* 2007;91:1048-53
- Yip LW, Thong BY, Lim J, et al. Ocular manifestations and complications of Stevens-Johnson syndrome and toxic epidermal necrolysis: an Asian series. *Eye* 2005;19:846-53.
- Haber J, Hopman W, Gomez M, Cartotto R: Late outcomes in adult survivors of toxic epidermal necrolysis after treatment in a burn center. *J Burn Care Rehabil* 2005;26:33-41
- Di Pascuale MA, Espana EM, Liu DT, et al. Correlation of corneal complications with eyelid cicatricial pathologies in patients with Stevens-Johnson syndrome and toxic epidermal necrolysis syndrome. *Ophthalmology* 2005;112:904-12
- Auquier-Dunant A, Mockenhaupt M, Naldi L, et al. Correlations between clinical patterns and causes of erythema multiforme majus, Stevens-Johnson syndrome, and toxic epidermal necrolysis. *Arch Dermatol* 2002;138:1019-24
- Kelemen JJ, Cioffi WG, McManus WF, et al. Burn center care for patients with toxic epidermal necrolysis. *J Am Coll Surg* 1995;180:273-8
- Murphy JT, Purdue GF, Hunt JL. Toxic epidermal necrolysis. *J Burn Care Rehabil* 1997;18:417-20
- McGee T, Munster A. Toxic epidermal necrolysis syndrome; mortality rate reduced with early referral to regional burn center. *Plast Reconstr Surg* 1998;102:1018-22
- Mittman N, Chan B, Knowles S, et al. Intravenous immunoglobulin use in patients with toxic epidermal necrolysis and Stevens-Johnson syndrome. *Am J Clin Dermatol* 2006;7:359-68
- Ahmed AR, Dahl MV. Consensus statement on the use of intravenous immunoglobulin therapy in the treatment of autoimmune mucocutaneous blistering diseases. *Arch Dermatol* 2003;139:1051-9
- Schneck J, Fagot J, Sekula P, et al. Effects of treatments on the mortality of Stevens-Johnson syndrome and toxic epidermal necrolysis: a retrospective study on patients included in the prospective EuroSCAR study. *J Am Acad Dermatol* 2008;58:33-40
- Chave TA, Mortimer NJ, Sladden MJ, et al. Toxic epidermal necrolysis: current evidence, practical management and future directions. *Br J Dermatol* 2005;153:241-53
- Arevalo JM, Lorente JA, Gonzalez-Herrada C, Jimenez-Reyes J. Treatment of toxic epidermal necrolysis with cyclosporine A. *J Trauma* 2000;48:473-8
- Aihara Y, Ito R, Ito S, et al. Toxic epidermal necrolysis in a child successfully treated with cyclosporin A and methylprednisolone. *Pediatr Int* 2007;49:659-62
- Robertson SM, Curtis MA, Schleich BA, et al. Ocular pharmaco-

- kinetics of moxifloxacin after topical treatment of animals and humans. *Surv Ophthalmol* 2005;50:S32-45
27. Wagner RS, Abelson MB, Shapiro A, Torkildsen G. Evaluation of moxifloxacin, ciprofloxacin, gatifloxacin, ofloxacin, and levofloxacin concentrations in human conjunctival tissue. *Arch Ophthalmol* 2005;123:1282-3
 28. Scheinfeld N. A review of deferasirox, bortezomib, dasatinib, and cyclosporine eye drops: possible uses and known side effects in cutaneous medicine. *J Drugs Dermatol* 2007;6:352-5
 29. Rosenthal P, Cotter J. The Boston Scleral Lens in the management of severe ocular surface disease. *Ophthalmol Clin North Am* 2003;16:89-93
 30. John T, Foulks GN, John ME, et al. Amniotic membrane in the surgical management of acute toxic epidermal necrolysis. *Ophthalmology* 2002;109:351-60
 31. Kobayashi A, Yoshita T, Sugiyama K, et al. Amniotic membrane transplantation in acute phase of toxic epidermal necrolysis with severe corneal involvement. *Ophthalmology* 2006;113:126-132
 32. Muquit M, Ellingham R, Daniel C. Technique of amniotic membrane transplant dressing in the management of acute Stevens-Johnson syndrome. *Br J Ophthalmol* 2007;91:1536
 33. Tandon A, Cackett P, Mulvihill A, Fleck B. Amniotic membrane grafting for conjunctival and lid surface disease in the acute phase of toxic epidermal necrolysis. *J AAPOS* 2007;11:612-3
 34. Dua HS, Gomes JAP, King AJ, Maharajan VS. The amniotic membrane in ophthalmology. *Surv Ophthalmol* 2004;49:51-77
 35. Gomes JA, Romano A, Santos MS, Dua HS. Amniotic membrane use in ophthalmology. *Curr Opin Ophthalmol* 2005;16:233-240
 36. Tseng SC, Espana EM, Kawakita T, et al. How does amniotic membrane work? *Ocul Surf* 2004;2:177-87
 37. Meller D, Pires RT, Mack RJ, et al. Amniotic membrane transplantation for acute chemical or thermal burns. *Ophthalmology* 2000;107:980-90.
 38. Tamhane A, Vajpayee RB, Biswas N, et al. Evaluation of amniotic membrane transplantation as an adjunct to medical therapy as compared with medical therapy alone in acute ocular burns. *Ophthalmology* 2005;112:1963-1969
 39. Solomon A, Meller D, Prabhasawat P, et al. Amniotic membrane grafts for nontraumatic corneal perforations, descemetocelles, and deep ulcers. *Ophthalmology* 2002;109:694-703
 40. Kruse FE, Rohrschneider K, Volcker HE. Multilayer amniotic membrane transplantation for reconstruction of deep corneal ulcers. *Ophthalmology* 1999;106:1504-11
 41. Bouchard CS, John T. Amniotic membrane transplantation in the management of severe ocular surface disease: indications and outcomes. *Ocul Surf* 2004;2:177-87
 42. Sekiyama E, Nakamura T, Kurihara E, Cooper LJ, Fullwood NJ, Takaoka M, Hamuro J, Kinoshita S. Novel sutureless transplantation of bioadhesive-coated, freeze-dried amniotic membrane for ocular surface reconstruction. *Invest Ophthalmol Vis Sci* 2007;48:1528-34.
 43. Uhlig CE, Busse H, Groppe M. Use of fibrin glue in fixation of amniotic membranes in sterile corneal ulceration. *Am J Ophthalmol* 2006;142:189-91
 44. Szurman P, Warga M, Grisanti S, et al. Sutureless amniotic membrane fixation using fibrin glue for ocular surface reconstruction in a rabbit model. *Cornea* 2006;25:460-6
 45. Hick S, Demers PE, Brunette I, et al. Amniotic membrane transplantation and fibrin glue in the management of corneal ulcers and perforations: a review of 33 cases. *Cornea* 2005;24:369-77