

# Hand and Wrist Problems for the General Practitioner

Professor David Warwick

MD FRCS FRCS (Orth).  
European Diploma of Hand Surgery

Consultant Hand Surgeon

University Hospitals Southampton

Jersey General Hospital

Wessex Nuffield Hospital; Spire Southampton Hospital; Sarum Road Hospital

Email: [davidwarwick@handsurgery.co.uk](mailto:davidwarwick@handsurgery.co.uk)

NHS: 023 80 995212

Private: 0845 4505 007

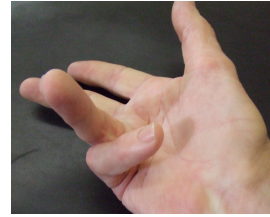Mobile: 07887 651451

[www.handsurgery.co.uk](http://www.handsurgery.co.uk)

[www.collagenase.co.uk](http://www.collagenase.co.uk)

## Dupuytren's Disease

This is a proliferation of the collagen within the palmar fascia which forms the pads in the palm and fingers separated by skin creases. The proliferating collagen thickens and contracts. About 60% give a clear family history. There is no occupational link, although occasionally a hand injury can precipitate the condition.



**Treatment in General Practice:** there is no medication, splint or exercise that can stop Dupuytren's. Small nodules in the palm need no treatment. They may be painful for a few months but the pain usually settles. The differential diagnosis is trigger finger and a flexor tendon sheath ganglion (qv).

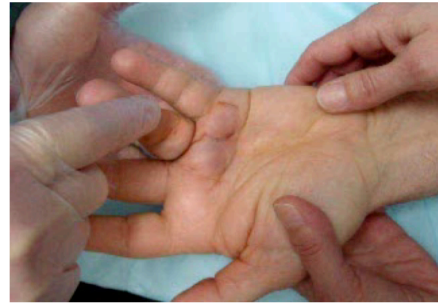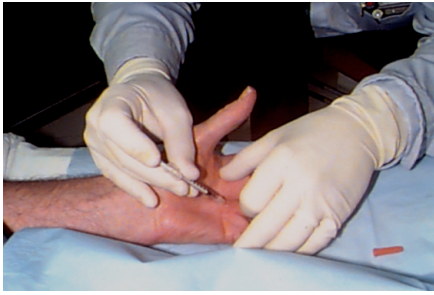**When to refer:** The patient should have a clear functional problem that would justify the (small) potential risks of surgery. As a rule, a loss of 30 degrees extension at the MCP joint or PIP joint tends to cause functional problems and is a reasonable threshold for surgery. Rapidly advancing disease, and disease in younger people with a strong family history, should be referred early rather than late, It can be difficult to correct the finger safely if the contracture is too far advanced. Dupuytren's surgery is not always straightforward and expert post-operative hand therapy is essential. Patients should be therefore be managed within a Hand Unit and not in a general orthopaedic setting.

**Treatment options:** simple cords in the palm can be treated in outpatients by "needle fasciotomy" with good early results. Recurrence is common and the technique can be dangerous because of the vicinity of the digital nerves in the finger. More significant disease is treated by removal of the cord ("fasciectomy") with closure of the wound by skin flaps ("z-plasty") or by a skin graft (especially in recurrent or aggressive disease or in younger patients with a strong family history). After surgery, the patient will not be able to drive or do heavy work until the wounds have settled- usually 3 weeks for simple surgery and 6 weeks for more complex surgery.. A splint may be used for those with more significant surgery.

### **Xiapex (Collagenase)**

This is an exciting new treatment. An enzyme is injected into the cord and the next day the finger is simply manipulated under a local anaesthetic. For suitable cases, this is an easy technique with much quicker recovery than surgery. The recurrence rate is probably slightly higher than surgery and the clinically relevant complication rate is certainly lower surgery.

See [www.collagenase.co.uk](http://www.collagenase.co.uk) for more details.



[www.collagenase.co.uk](http://www.collagenase.co.uk)

## Tingling Fingers

### Carpal tunnel syndrome

**Anatomy:** *The median nerve* supplies the abductor pollicis brevis, opponens pollicis as well as lumbricals to the middle and index fingers; it also innervates the palmar skin of the thumb, index and middle fingers and the radial half of the ring finger. In carpal tunnel syndrome, the nerve is compressed as it runs beneath the transverse ligament (between the bone pillars at the heel of the hand).

**Presentation.** Carpal tunnel syndrome typically presents with tingling in the middle and index fingers, often worse at night. There is a reflex to shake the hand or hang it out of the bed. Gripping a steering wheel or holding a book often provoke the symptoms. In later stages there is loss of dexterity due to numbness of the index finger and thumb as well as weakness of the thenar muscles. It is *not* more common in typists but is possibly related to repetitive power grip in flexion.

**Examination.** Tinel's percussion sign (tapping with the finger tip over the carpal tunnel and especially just proximal to the carpal tunnel), is positive in 90%. Phalen's wrist flexion test (bending the wrist forward) provokes tingling within 60 seconds

**Treatment in general practice.** In the early stages, particularly in those with an inflammatory disorder or during late pregnancy, a *steroid injection* can help. However, there is a real danger of damaging the median nerve (withdraw if there is any pain or tingling!). For those with nocturnal symptoms, a *wrist splint* is often helpful- it prevents wrist flexion which otherwise increases pressure in the carpal tunnel).

Do not order *nerve conduction studies* for obvious carpal tunnel syndrome- save this test for those with a confusing clinical picture.

**When to refer.** If symptoms are troublesome, then the patient should be referred.

The referral should be *urgent* if there is established numbness, loss of dexterity or muscle wasting.

**Carpal tunnel surgery.** This cures night-time tingling straightaway in almost everyone. Reduced dexterity and numbness may not recover, especially in those over 60 or 70 years of age. Patients cannot drive for about 2 ½ weeks. The scar is often sore and grip reduced for 5 or 6 weeks.

## Ulnar nerve compression

**Anatomy:** The ulnar nerve supplies the hypothenar muscles, all the interossei, lumbricals to the little and ring fingers, flexor pollicis brevis and adductor pollicis. Sensory branches innervate the palmar and dorsal skin of the little finger and the ulnar half of the ring finger. The ulnar nerve is usually compressed behind the medial epicondyle. It is, very occasionally, trapped as it runs into the palm of the hand through Guyon's Canal (just radial to the pisiform).

**Presentation:** the patient has tingling in the little and ring fingers. This may be related to flexion of the elbow or leaning on the inner side of the elbow. In later stages there is loss of grip and wasting of the hypothenar eminence. Tinel's percussion test is usually positive behind the medial epicondyle (but compare with the other side)

### Key Points: Tingling fingers

**Possible diagnoses:** carpal tunnel; cubital tunnel; cervicogenic neuropathy; general neurological disorder

**When to refer:** *muscle wasting* and *established numbness* need *urgent* referral as they may not recover if left for too long; sleep loss; troublesome tingling. Neurological problems elsewhere.

**What to do before referral:** try a night splint for nocturnal carpal tunnel symptoms, tell patient to avoid elbow flexion or leaning on elbow for cubital tunnel symptoms.

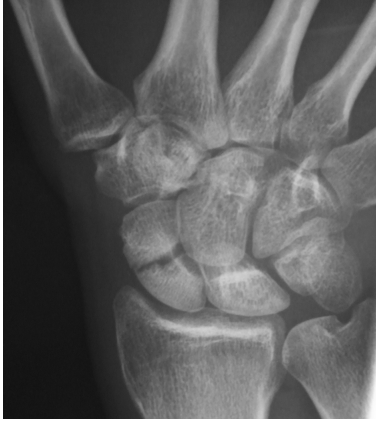**Nerve studies:** do *not* order if clear diagnosis of carpal tunnel syndrome. Helpful if diagnosis unclear

**Treatment in General Practice:** there is no role for injections or splintage. If there is a clear relationship to flexion of, or leaning upon, the elbow, then advise the patient to desist.

**When to refer:** intrusive symptoms warrant referral. If there is established numbness or muscle wasting, then referral should be urgent. The nerve is released surgically with a small incision behind the elbow. The wound recovers quickly (within 2 weeks). Nasty tingling also responds promptly. Muscle wasting may take a long time, if at all, to recover, hence the need for urgent referral if this presents.

## Painful wrist

### How to NOT miss a scaphoid fracture



A fall on the outstretched hand can cause various injuries- some easy to diagnose (distal radius fractures), some easy to miss (scaphoid fractures) and some that are difficult to diagnose (ligament injuries).

A missed scaphoid fracture is the commonest cause of a successful negligence claim with a hand or wrist problem against GPs and junior hospital doctors. The consequences (for the patient and the Indemnity organisations) can be huge because of the lost opportunity to treat the fracture successfully.

A forced hyperextension of the wrist (eg a fall on the outstretched hand, or a bad soccer ball catch) is a scaphoid fracture until proven otherwise. The wrist must be thoroughly examined. Not just the anatomical snuffbox (ie the dent at the back of the thumb base) but also the scaphoid tubercle, back of the wrist joint and both front and back of the entire distal radius. If there is any tenderness at all, the patient needs *specific scaphoid xrays* (which include 4 views). Even if the xrays are reported as normal, if the patient has persisting pain, then the xrays should be repeated after 2 weeks (or referred via the Emergency Department for an urgent MRI). If a fracture is not treated within 4 weeks then it will probably not heal and an uncertain future looms.

#### Key points: Scaphoid fracture

**Mechanism:** Forced hyperextension of the wrist

**Symptoms:** Wrist pain (often quite mild)

**Examination:** tenderness over scaphoid tubercle and/or anatomical snuffbox and/or dorso-radial wrist and/or pain on telescoping thumb

**Xrays:** any tenderness justifies *specific scaphoid views*. If normal but still painful or tender 2 weeks later, *repeat*

### Causes of Wrist Pain

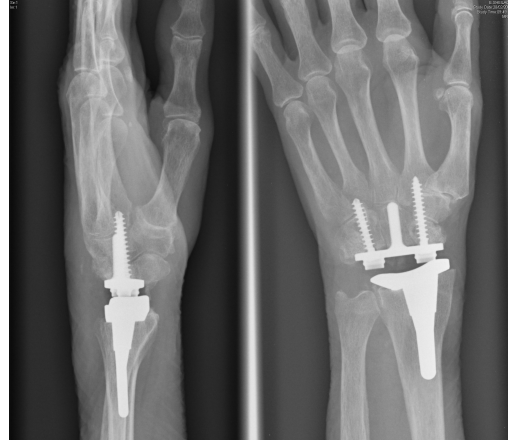**Sudden acute wrist pain** - the most common causes are gout, pseudogout (pyrophosphate deposition) and infection. These conditions should be referred urgently because of the risk of missing an infection which can destroy the wrist rapidly. Serum urate is unreliable for acute gout- usually normal.

**Chronic wrist pain:** There are many causes of wrist pain- some are common, some are rare. Diagnoses include ligament ruptures, osteoarthritis, Kienbock's disease (lunate avascular necrosis), triangular cartilage ruptures, undisclosed fractures, occult ganglion, dorsal synovial impingement. A plain x-ray can diagnose some but not all of these diagnoses. Intrusive and prolonged symptoms warrant referral to the Hand Clinic.

## Wrist arthritis

This is quite rare. It can happen spontaneously or following a significant injury such as a scaphoid fracture, radius fracture or scapho-lunate ligament rupture.

Presentation: The patient presents with stiffness, pain and reduced grip which gradually worsens. On examination the wrist is usually swollen over the dorsal-radial aspect; the wrist is always tender with reduced movement. X-rays confirm the diagnosis.



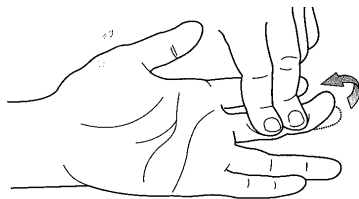
**Treatment in General Practice:** *anti-inflammatory drugs* and a *splint* can help. Injections into the wrist joint are also helpful for a while, if the GP is trained to do this.

**When to refer:** Intrusive symptoms justify referral. The diagnosis is confirmed and one or two injections given to see if these can offer a longer-term relief. If not then surgery is discussed. Wrist replacement, partial wrist fusion or total wrist fusion are all options.

## Injured fingers

### Cuts

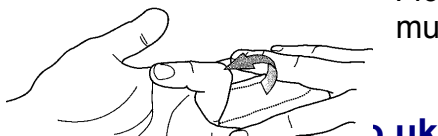
The multitude of structures in the hand are exposed to injury with a sharp implement. The tendons and nerves must be carefully examined.



Test to check integrity of FDP.

*Flexor digitorum profundus*, the PIP joint is held in extension and the patient is then asked to bend the tip of the finger.

*Flexor digitorum superficialis*, the flexor profundus must first be neutralised. The fingers are all held in



extension by the examiner- this prevents the FDP from pulling down the finger as it has a common muscle belly in the forearm. The patient is then asked to bend the PIP joint. There are two exceptions to this rule: Firstly, the little finger sometimes has no independent flexor digitorum superficialis. Secondly, the index finger often has an entirely separate flexor profundus, which is not inactivated by holding all the finger tips straight. The patient is instead asked to pinch hard with the distal interphalangeal joint in full extension and the proximal interphalangeal joint in full flexion; this position can be maintained only by an intact superficialis tendon.

*Flexor pollicis longus:* the thumb, the thumb metacarpo-phalangeal joint is immobilised by the examiner in extension and then the patient is asked to bend the thumb tip.

*Extensor digitorum:* the patient is asked to extend the individual metacarpophalangeal joints

*Digital nerves:* the sensation to each side of the finger is tested with a needle and with light touch.

*Median nerve:* sensation over the tips of the middle finger, index finger and thumb; power of the thenar eminence (the pulp of muscle at the base of the thumb)

*Ulnar nerve:* sensation: over the pulp of the little finger; power of the abductor digiti minimi and first dorsal interosseous (ask the patient to spread the little finger and index finger sideways against resistance).

**When to refer:** any cut that goes through the skin with *the slightest suspicion or smallest chance* of injury to a tendon or nerve in the hand or wrist should be referred to the A & E Department or Hand Clinic (by telephone) straightaway .

## Broken fingers

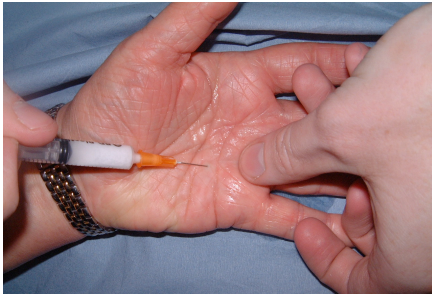A wrench or crush can break a phalanx or dislocate a joint. Any digit that is deformed or tender should be referred for an x-ray. A dislocated joint can be reduced under local anaesthetic in the GP surgery. However, this can aggravate certain intra-articular fractures and nowadays it is wiser to refer for an xray prior to such manipulation.

# Tendon problems

## Trigger finger

The flexor tendon snags at the opening of the flexor sheath, causing the finger to lock down at the PIP joint. The patient has to snap the finger straight. It is often worse first thing in the morning. It is more common in diabetes, It is not related to work. Not all trigger fingers lock- there may just be a painful nodule, especially in diabetes. In the thumb, the problem may be loss of flexion rather than locking in flexion; the tell-tale tender nodule at the front of the thumb MCP joint clinches the diagnosis.

**Examination:** there is a tender nodule in the palm at the level of the distal palmar crease.



**Treatment in General Practice:** A cortisone injection (eg 0.3ml depomedrone) cures 70%. The needle is inserted about 5mm in the midline at the level of the distal palmar crease, pointing 30 degrees distally. Do not inject against resistance (an intra-tendinous injection could cause a rupture).

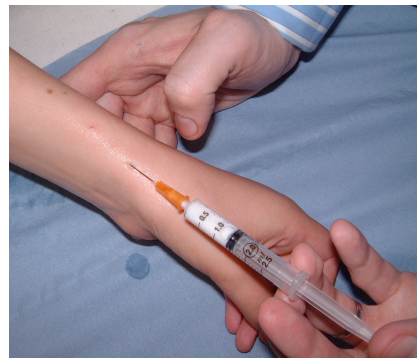**When to refer:** if one or two injections fail, refer for release. This is done under a local anaesthetic with a 98% cure rate.,

## De Quervain's Syndrome

The Abductor Pollicis Longus and Extensor Pollicis Brevis tendons are constricted as they pass beneath the sheath at the back of the thumb base.

**Examination:** tender and swollen over the radial styloid. Resisted thumb abduction ("hitch-hiker's sign") and passive flexion of the thumb right across the palm ("Finkelstein's test") are very painful.,

**Treatment in General Practice:** Physiotherapy is usually too painful and gels are not effective. Try a steroid injection- this cures 70%. The needle is inserted into the skin about 8mm distal to the radial styloid, directed proximally. About 0.3 ml is injected.



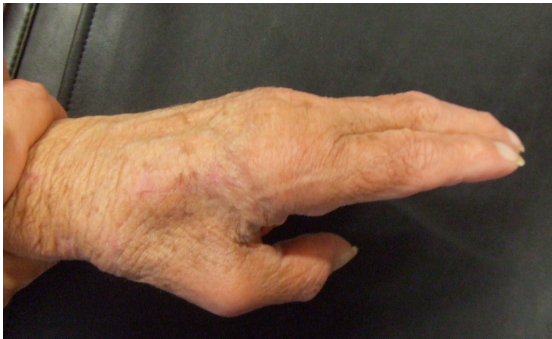**When to refer:** intrusive symptoms despite one or two injections justify surgery which has a 90% cure.



## Work-Related Upper Limb Disorder

This is a controversial topic. The acronym RSI (“repetitive strain injury”) should be avoided. It is inaccurate (repetitive use is generally good, not bad; the term injury implies damage which is rarely the case). The liberal use of the term RSI may deny the search for a defined treatable condition such as de Quervain’s, arthritis or carpal tunnel syndrome. The term also implies blame- which is usually unjustified and which can lead to prolonged litigation, stress and loss of employment prospects. A more suitable perspective is that some people feel symptoms at work through no fault of their own or anyone else’s. The term “Work Related Upper Limb Disorder” is preferred as it acknowledges that the symptoms are noticed at work but does not imply causation.

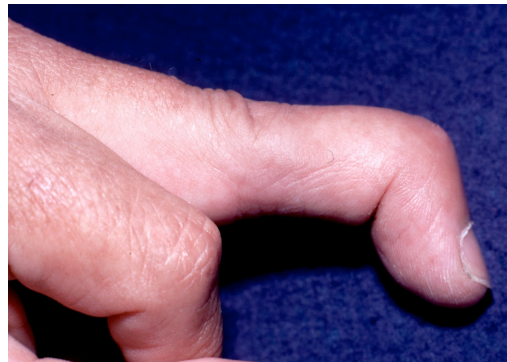## Ruptured tendons



In rheumatoid arthritis or following trauma, tendons can rupture, causing various deformities such as a dropped knuckle, boutonniere and swan neck. If a finger looks strange and is not functioning properly, then referral to the Hand Clinic is advised. The picture shows an EPL rupture, which occurs in rheumatoid and after a Colles’ fracture.

## Mallet finger

This occurs when the tip of the finger is forcibly flexed. It often occurs in an innocent way such as tucking in the sheets under a bed. The tip of the finger should be splinted out straight with a tongue depressor or stiff plastic strip. An x-ray should be arranged to exclude a fracture. The tip must be splinted constantly for 8 weeks and then for 4 weeks at night. A proprietary “Stack” splint or even better a customised splint made by a Hand Therapist is most suitable. Even when presenting late prolonged splintage is effective. Surgery is rarely advised unless there is a displaced fracture or the deformity does not respond to splinting.



# Lumps on the Hand and Wrist

## Dorsal Ganglion

These are common and occur at any age, but usually under 35 years.. They arise spontaneously and are usually painless.

**Examination:** There is a soft swelling over the middle of the back of the wrist. Wrist movement is full and pain-free.

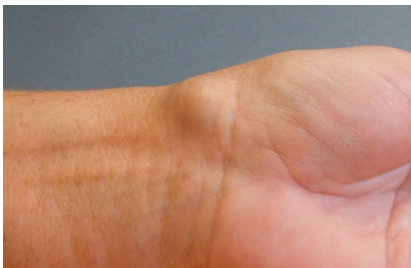**Treatment in General Practice:** The ganglion should be aspirated under sterile conditions with a green needle. Gel emerges and the cyst deflates.

**When to refer:** If the ganglion has been present for more than 6 months and one or two aspirations fail, then consider referral. Also, a painful ganglion may represent a more significant pathology (eg osteoarthritis) and should be referred, The ganglion can be removed surgically but 20% recur.

## Volar Ganglion

These are less common than a dorsal ganglion. There may be a wrist pain from an underlying arthritis of the STT (scaphoid-trapezium-trapezoid) joint.

**Examination:** soft swelling over the front of the radial edge of the distal radius. Stressing the STT joint (moving the wrist radial-wards and ulnar-wards under compression) may be painful if there is an associated STT arthritis.



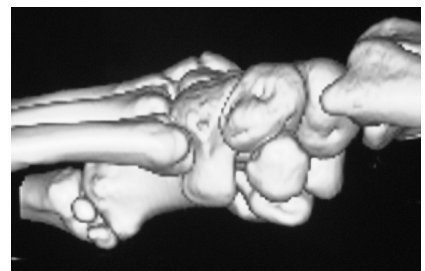
**Treatment in General Practice:** Aspiration can be tried but the radial artery is very close by and can be damaged,

**When to refer:** if the ganglion is painful, and does not resolve spontaneously over 6 months, then refer for consideration of removal.

## Metacarpal boss

This is a hard bony swelling over the back of the base of the 2<sup>nd</sup> and 3<sup>rd</sup> carpo-metacarpal joints (see CT scan). Many people have these and they are usually asymptomatic. If they are painful then there is usually an instability of the joint (which is usually rigid).

**When to refer:** if the lump is painful then it should be



referred for possible excision or joint fusion.

## Flexor tendon sheath ganglion

This is a 6mm hard tender lump at the front of the base of the finger, caused by a pouting in the flexor tendon sheath. It is called by the pathologist a “seed ganglion” or a “pearl ganglion” because of its appearance. The patient complains of a painful lump noticed when gripping.

**Treatment in General Practice:** the ganglion can be popped with a blue needle and this is often curable.

**When to refer:** if popping fails or the lump recurs then refer for excision under a local anaesthetic.

## DIP cyst

This is sometimes called a mucoid cyst or myxoid cyst or nail-bed cyst. A swelling appears over the dorso-radial or dorso-ulnar corner of the distal interphalangeal joint. There is usually an underlying osteoarthritis. The cyst pushes on the germinal matrix of the nail causing a groove. The cysts sometimes burst and occasionally get infected.

**Treatment in General Practice:** the cyst should be left alone if asymptomatic. If painful or repeatedly discharging then refer for surgical excision.

## Sarcoma

This is a vanishingly rare problem. Nevertheless, any lump is malignant until proven otherwise. If there is anything odd about a lump- its appearance, consistency or pain, then the patient should be urgently referred.

## Painful thumbs

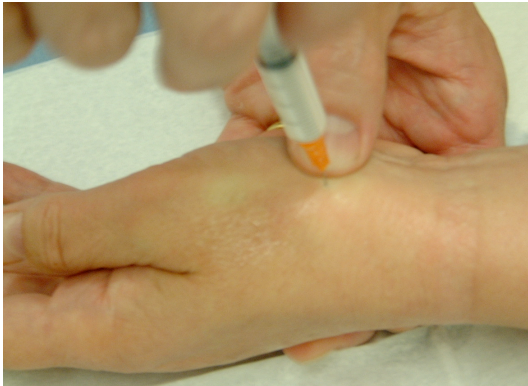### Thumb base arthritis

This is very common- 15% of females over the age of 55 have thumb base arthritis. It is often isolated, not necessarily related to arthritis in larger joints elsewhere although there are often Heberdon’s nodes (qv).

**Presentation:** the thumb base is painful; the patient points to the back of the carpo-metacarpal joint. The pain is aggravated by use, especially on pinching. Undoing bottle-tops becomes impossible. On examination there is tenderness over the base of the thumb moving the joint passively may cause painful crepitus. In more advanced cases the thumb base becomes fixed in adduction and, to

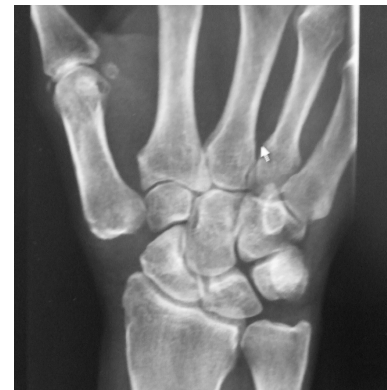maintain an adequate thumb span, the metacarpo-phalangeal joint hyper-extends.

**Treatment in General Practice:** advise the patient that for some patients the



symptoms fluctuate and may fade away. NSAID;s can help a flare up. The patient can be referred for a *splint* (but these are cumbersome and often discarded). A *steroid injection* can be very effective, particularly in disease with mild x-ray changes. A small dose (0.3mls) is given in the dorsal aspect of *the joint* (see picture). *X-rays must be specific for the thumb- ask for a "Robert's view"*. Normal hand or wrist x-rays will not define the diagnosis.

**When to refer:** patients with intrusive symptoms which have not settled with time or which have not responded to one or two injections should be referred. Surgery (usually trapeziectomy-see picture- but sometimes joint replacement) is very effective in around 85% of people and the results are durable.



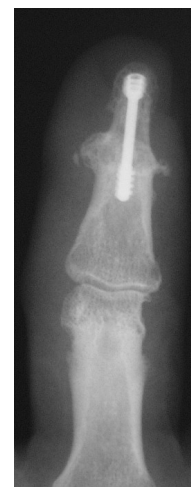## Painful fingers

### Heberdon's nodes

These are knobby finger tips, caused by arthritis of the DIP joint. It is genetically determined. Fortunately, for most patients, the joints are pain-free and function well, even if unsightly and stiff. The joint can develop a ganglion (qv).

**Treatment in General Practice:** most patients can be reassured. If the nodules are painful they can be injected using a fine dental needle. A thimble splint can be worn.

**When to refer:** injecting this small joint is challenging and so the GP may prefer to refer for this. The traditional surgical option is fusion; if the joint is so painful or deformed that the patient would rather it were fused then refer for surgery. The option of joint replacement can now also be considered.

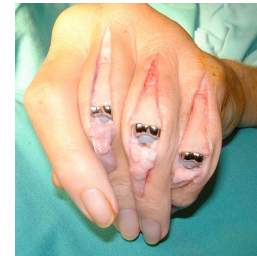
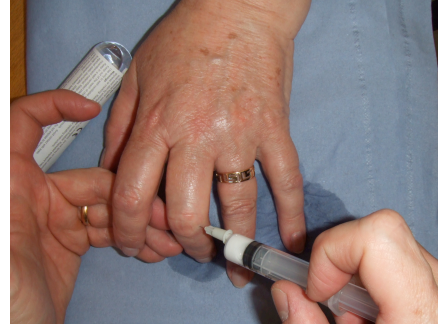

## Bouchard's nodes

These are caused by osteoarthritis of the PIP joints. They are more likely to be part of a more generalised small joint arthritis of the hand. Pain, stiffness and reduced function can be very troublesome

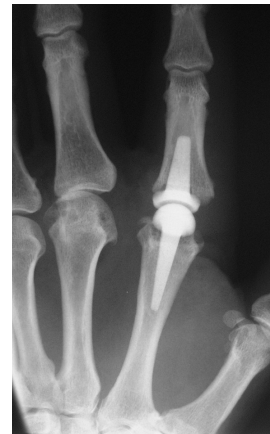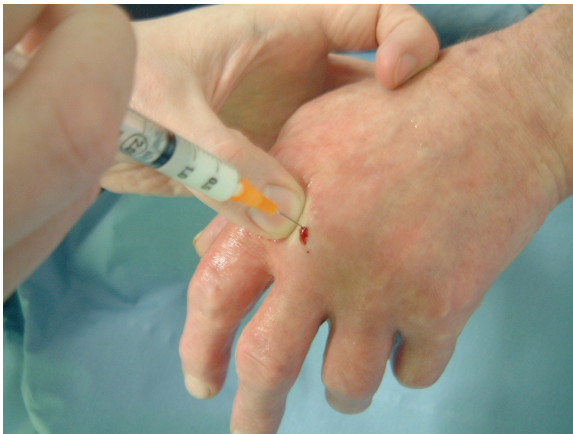**Treatment in General Practice:** *Reassure* the patients that the pain fluctuates and can settle (although the deformity and stiffness won't). *Cortisone injections* help for a while.

**When to refer:** surgery with modern *joint replacements* made from pyrocarbon (graphite) or polythene-chrome (like a knee replacement) can be very helpful.



## Metacarpophalangeal joint arthritis

This is rare and has a curious association with haemochromatosis. Management is the same as for Bouchard's nodes. Injections are often very helpful; joint replacement can be very effective.



## Skin problems

The skin can be plagued by many skin problems, ranging from benign rashes (eczema) to systemic manifestations (eg psoriasis), pre-malignant lesions (Bowen's disease) and frankly malignant tumours (malignant melanoma,

squamous cell carcinoma, basal cell carcinoma) .

**When to refer:** any suspicious or persistent skin lesion should be referred through the local protocol- often dermatology or for more “surgical” lesions, to the Hand Surgery or Plastic surgery unit.

## Infections

Infections in the hand can cause devastating problems. Early recognition and management is crucial. Diabetes, steroids, immunosuppression and drug abuse are risk factors. Most infections will settle with antibiotics, elevation and rest. However malaise, spreading cellulites or suspicion of joint involvement warrant immediate referral.

### Tendon sheath infection

A penetrating injury over the front of the finger can infect the tendon sheath. Pus in this enclosed space can destroy the tendon within hours. If Kanavel's signs are positive immediate referral is mandatory.

#### Kanavel's Signs of Flexor Sheath Infection

- Flexed posture of digit
- Tenderness along the course of the tendon
- Pain on passive finger extension

### Animal bites

Animal bites can cause rapidly spreading infection; they may also of course damage the structures in the hand. **Augmentin** should be commenced straightaway; If there is any suspicion whatsoever of structural damage or spreading sepsis then the patient must be referred straightaway to the Emergency Department.

### Human bites

These are more sinister than animal bites. It is especially important not to miss a “fight-bite”, in which an opponents' tooth penetrates the knuckle. At first they appear benign but within hours the joint fills with pus and is destroyed. Immediate referral, however innocuous the wound, is needed.

### Pressure injection injury

High pressure injection of paint and grease causes a small innocent punctum; however the material has been forced throughout the tissue planes and major debridement is urgently required.