



# Imaging of the Male Genital Tract: A Review of the Mechanism of Sperm Quality Impairment in Infertility

Silvia W. Lestari<sup>1,2\*</sup>, Andrian Japari<sup>2,3</sup>, Daniel Makes<sup>4</sup>, Gito Wasian<sup>2</sup>, Judie Hartono<sup>2</sup>, Petrus Supardi<sup>2</sup>, Andon Hestiantoro<sup>5</sup>

<sup>1</sup> Department of Medical Biology, Faculty of Medicine Universitas Indonesia

<sup>2</sup> Andrology Specialist Program, Faculty of Medicine Universitas Airlangga/Dr. Soetomo Hospital Surabaya, Indonesia

<sup>3</sup> Infertility Unit, Telogorejo Hospital, Semarang, Indonesia

<sup>4</sup> Jakarta World Federation of Ultrasound in Medicine and Biology, Center of Education, Indonesia

<sup>5</sup> Department of Obstetrics and Gynecology, Faculty of Medicine Universitas Indonesia/Dr. Ciptomangunkusumo Hospital Jakarta, Indonesia.

## ABSTRACT

Male infertility is generally diagnosed by anamnesis, physical examination, and also semen analysis. But, in some cases, imaging methods need to be used for additional help to find out the cause of infertility. A literature search from the PubMed database was performed using keywords of male genital tract imaging, sperm quality impairment, and infertility cases to find appropriate articles, then all results were collected and selected. The most common cause of male infertility is varicocele semen analysis followed by testicular atrophy, microlithiasis, undescended testis (UDT) or inflammation, which can impair spermatogenesis. Ejaculatory duct obstruction also causes blockage of sperm passage. Additional knowledge of the mechanism of sperm quality impairment, and accompanied by male genital tract imaging, is expected to help the clinician to decide more specific pathological management in andrological cases.

**Key Words:** imaging, male genital tract, sperm quality, andrology cases, infertility.

eIJPPR 2020; 10(1):87-96

**HOW TO CITE THIS ARTICLE:** Silvia W. Lestari, Andrian Japari, Daniel Makes, Gito Wasian, Judie Hartono, Petrus Supardi, Andon Hestiantoro (2020). "Imaging of the Male Genital Tract: A Review of the Mechanism of Sperm Quality Impairment in Infertility", International Journal of Pharmaceutical and Phytopharmacological Research, 10(1), pp.87-96.

## INTRODUCTION

Infertility is defined as an inability to conceive after regular unprotected sexual intercourse for one year. [1] In one study population revealed that 84% of women can reach clinical pregnancy in the first year of unprotected sexual intercourse regularly. [2-5] A multicentre study conducted by WHO showed that infertility can be caused by either male or female factors equally. [6] By thorough anamnesis and comprehensive physical examination, a possible cause of infertility can be determined, even if a more thorough examination is required [7].

It is estimated that men of reproductive age may experience reproductive problems, either in the testes, pre-testicular, or post-testicular. Semen analysis is the most common examination to evaluate spermatozoa

quality in male infertility cases. However, sperm analysis does not always confirm the cause of infertility. The abnormalities of the semen analysis result can be due to decreased spermatozoa quantity or concentration (oligozoospermia), impaired sperm motility (astenozoospermia), and the low number of normal sperm morphology (teratozoospermia), or in combination with previously mentioned, or even absent spermatozoa (azoospermia).

Male genital tract imaging can also be used as a method of identifying causes that are not identified in a routine examination. Advances in imaging technology, especially in image quality and resolution, the use of USG (ultrasonography), the use of high-frequency sound waves for imaging, become common use in andrology clinics to evaluate male reproductive problems. [8, 9] Using *Trans-*

**Corresponding author:** Silvia W. Lestari

**Address:** Jl. Salemba Raya No. 6, Jakarta, Indonesia, 10430. Tel: (021) 31930379. Fax: (021) 31907281.

**E-mail:** ✉ Finallysilvia@gmail.com

**Relevant conflicts of interest/financial disclosures:** The authors declare that the research was conducted in the absence of any commercial or financial relationships that could be construed as a potential conflict of interest.

**Received:** 01 August 2019; **Revised:** 27 February 2019; **Accepted:** 12 January 2020



Rectal UltraSonography (TRUS), Doppler ultrasonography and Magnetic Resonance Imaging (MRI) also were other options to find the cause of male infertility. This review analyzes the results of the male reproductive tract imaging commonly found in various cases of infertility, using either the mechanism or the pathophysiology of factors that impair sperm quality or abnormalities of semen analysis results. [10]

### Infertility

Infertility is recognized as a condition, while married couples are not able to survive and gave birth to a live baby, and are regularly having unprotected sex for 12 months. [11] Based on the anatomy of the male reproductive tract, male infertility can be divided into three major part, namely: [12]

- a. Pre testicular: Disorders in the male reproductive system that affect the spermatogenesis process, such as hormonal imbalance, either caused by genetic factors or nongenetic factors, e.g. hypogonadism.
- b. Testicular
- c. disruptions of the testicles, or surrounding structures, either directly or indirectly affecting the testes, e.g. varicocele, cryptorchidism, and gonadotoxin.
- d. Post testicular
- e. disruptions of male reproductive tract located after the testes, which affecting the ejaculatory path or sperm motility, e.g. reproductive tract obstruction (epididymis, vas deferens or ejaculatory duct)

Just like any other diseases, the evaluation of male infertility begins with anamnesis, followed by a physical examination and, where necessary, laboratory testing. A common laboratory testing is a semen analysis, which if resulted is abnormal, indicating fertility problems. The following is a regular reference to the WHO semen analysis (Table 1). [13] Semen analysis abnormalities can be in the form of oligozoospermia, which is a decrease of sperm quantity or concentration, asthenozoospermia which is the low number of progressively motile sperm, teratozoospermia which is a small number of sperm with normal morphology, or in combination, such as oligoasthenozoospermia or even azoospermia which is characterized by the absence of spermatozoa in the seminal plasma.

**Table 1: Normal Semen Reference Analysis [13]**

No.	Parameter Analisis Semen	WHO 2010
1.	Concentration	15 million/ml
2.	Motility	
	A. Progressive	32 %
	B. Nonprogressive	1 %

	C. Immotile	22 %
3.	Morphology	4 %
4.	Total sperm count/ ejaculate	39 million

Even though in evaluating male infertility we have performed anamnesis, physical examination, and laboratory tests, sometimes we still need to do more investigation to find the main cause of infertility to make a proper diagnosis, or decision about proper management, such as the genital tract imaging.

### Varicocele

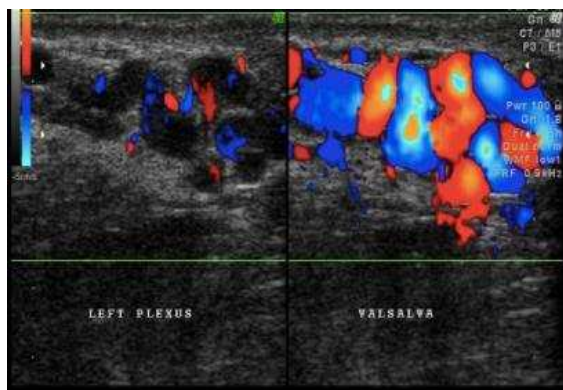
Abnormal dilatation of the pampiniform plexus is called varicocele. This abnormality is characterized by a presence of backflow of the vein, and in almost cases occurred on the left side. [14] Varicocele is almost absent in 11-year-old boys, but the prevalence is rising as men grew older, as high as 15% in adult men population. [15] Varicocele is differentiated into three classes: [16]

- I. palpable on Valsalva maneuver.
- II. easily palpable, even without the Valsalva maneuver.
- III. visible

Internal spermatic vein venography has long been considered the gold standard or the diagnostic of varicocele since a long time ago, due to the smallest difference in technical variations and variability between examiners. [17, 18] Alas, this examination took longer, more aggressively as well as radiation. [18] For these reasons, venography is only indicated in limited cases nowadays. [18] In present, the American Urology/American Society for Reproductive Medicine (AUA/ASRM) is suggesting to diagnose varicocele with physical examination and then the confirmation of the diagnoses is defined by the use of ultrasonography, especially when naught can be concluded in physical examination. [19] Compared to venography, physical examinations in the diagnosis of varicocele have a sensitivity of 50-70%, whereas scrotal ultrasonography has a sensitivity of 93%. [14, 17] Due to this reason, scrotal ultrasonography becomes well accepted and widely used for the diagnosing of varicocele. [17] A study in West Africa proved that varicocele was the most common ultrasonographic abnormality in sub-fertile patients. [20]

Varicoceles are shown as an abnormal dilatation of pampiniform plexus in ultrasonography, which is characterized by the presence of backflow of the veins, which were most evident with the Valsalva maneuver. [14] This dilatation is markedly obvious by the Doppler examination (Figure 1). Based on the findings of ultrasonography, varicocele is graded into [18]

1. no varicocele is seen, even in the Valsalva maneuver
2. small varicocele is seen in the Valsalva maneuver
3. large varicocele
4. large varicocele, which most evident in the Valsalva maneuver or standing position
5. evident varicocele in every position (standing and resting)



**Figure 1: Varicocele (original figure with permission from radiologist)**

The concept of pathophysiology mechanism of semen analysis abnormalities that disrupt the male reproductive system has been proposed by Telli et al. (2015), either by the direct mechanism that impair the process of spermatogenesis through hormonal imbalance, testicular hypoxia, and scrotal hyperthermia, or, by an indirect mechanism that raises the level of *reactive oxygen species* (ROS) that may lead to sperm membrane peroxidation, DNA fragmentation, and apoptosis. [21]

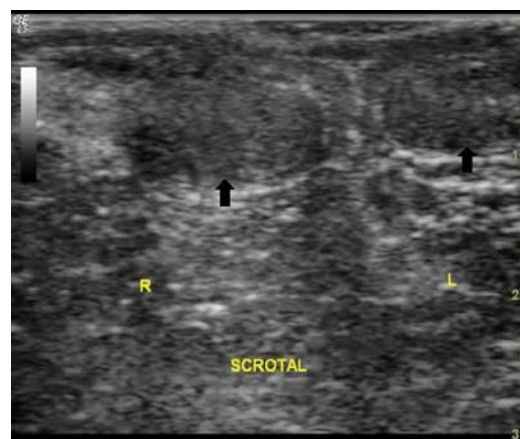
A study revealed that varicocele affects sperm quality, in sperm concentration and function, an elevated level of oxidative stress and DNA fragmentation. [22] A more specialized study of DNA fragmentation in varicocele also performed by Chak-Lam Cho revealed the same result with studies done previously. [23] However, research by Zini and Bowman has also shown that the opposite is true, revealing 75% of men with varicocele have a normal semen analysis. [24]

Another study showed that improvement in semen analysis after varicocelectomy was achieved, especially in sperm concentration, sperm motility, and sperm morphology. [24] These results are also justified by a meta-analysis that not only reports the same results but also shows lower levels of DNA damage and oxidative stress. [25]

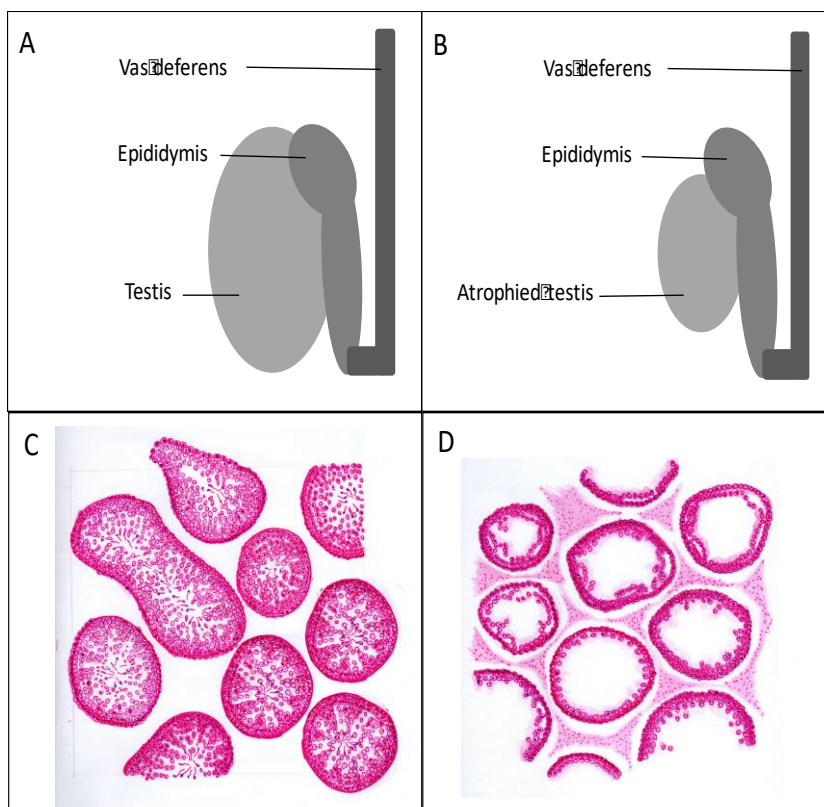
### Testicular atrophy

Testicular atrophy can occur after inflammation process, infection, testicular torsion, hematomas causing testicular ischemia, ischemic orchitis. [26] Ultrasonography examination can help measure testicular volume. Normal testicular volume in adult men averages  $18.6 \pm 4.8$  ml. [27] In testicular atrophy, shrinkage in testicular volume can be evaluated. (Figure 2). [8] Other findings include a decrease in reflexivity, and testicular vascularization, although the epididymis appears normal. [28] Testicular volume below 12 ml is closely related to testicular function abnormality. [28] Laboratory examination revealed that there was a decrease in plasma testosterone levels and elevated FSH and LH levels.

Testicular atrophy also causes testosterone imbalance and estrogen levels, which results in various clinical manifestations, including gynecomastia, erectile dysfunction, infertility, and female-like pubic hair distribution pattern. [29] Gynecomastia becomes the most evident proof of hormonal imbalance. [30] Low testosterone level induces diminished libido, erectile dysfunction, changes in secondary sex characteristics, and impairment of spermatogenesis process which all lead to infertility. [31] In cross-sectional histopathology of the testicular tubules, there is a marked difference between the normal testicle and the atrophic testicle whereas in normal testicle spermatogenesis is still optimal (complete set of spermatogenic cells), and in the atrophied testicle, the process of spermatogenesis is impaired (incomplete set of spermatogenic cells) (Figure 3).



**Figure 2: Atrophied testicle (original figure with permission from radiologist)**



**Figure 3:** Volume and histopathology of the testicle. A and C. Normal testicle, B and D. Atrophied testicle (original figures provided by the first author).

### microlithiasis

Testicular microlithiasis was first reported approximately 35 years ago. [32] This condition cannot be determined by physical examination, and can only be detected and diagnosed using testicular ultrasonography. Doherty et al. (1987) defined testicular microlithiasis as the presence of 5 calcification spots in one or more ultrasonographic units (Figure 4A) [32, 33] Testicular microliths are formed by several germinal cells originated from unstable spermatogenic epithelial which arose into the lumen of seminiferous tubules. Surrounding these cells, collagen layers are formed together with a calcium salt. [34] These microliths are very small and measure 1 to 3 micrometers, making it rare to find them in testicular biopsies, although they are sometimes seen occasionally. (Figure 4B) [35] Even though the diameter of the microliths is less than 1 mm, they are still too large to be able to vacate the seminiferous tubules. Nevertheless, some reports stated that testicular microliths have been observed in the rete testis, or even in the epididymis. [36]

The incidence of testicular microlithiasis in the healthy adult men population (aged 17-35 years old) is 5,6%, and the incidence is higher in the Afro-American (14,1%). [37] Microlithiasis was also associated with ethnicity and socioeconomic status. [38] (Pedersen MR et al., 2017) In boys, the incidence of microlithiasis is lower (1,1% and 4,2%). [39] Testicular microlithiasis is reported for being related to infertility, and other health-related conditions,

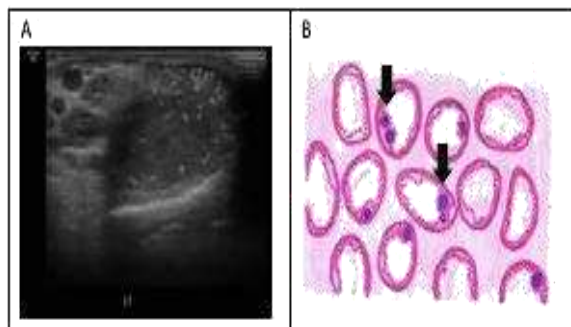
especially in malignancy (carcinoma in situ), testicular dysgenesis, and Down's Syndrome. [36, 40-43] In terms of infertility, one study has shown that semen analysis of infertile men is the same as the ones from fertile men with microlithiasis. In addition, the correlation between microlithiasis and primary infertility was 46% and with secondary infertility 39%, approximately 4 to 5 times higher than in the fertile men. [44]

Testicular microlithiasis may not be a serious pathological condition, but it can become a marker for testicular diseases, an indicator for testicular malignancy or benign lesion of the testicular with the potential transformation to a malignancy. [45] This might be closely related to some kind of testicular pathologies, although testicular pathologies may not be easy to prove in any patient with microlithiasis.

With the consideration that testicular microlithiasis prevalence is quite high, as high as 6%, showed that routine testicular ultrasonography would become a very important diagnostic modality. Likewise, advanced clinical management is recommended for this kind of condition, by germinal cell malignancy in the testicle, and unclassified intratubular germinal cell neoplasia. Fortunately, follow up study for 5 years revealed that none of them developed into malignancy. For this reason, a low-risk conclusion was drawn. However, routine follow up for men with microlithiasis should be performed, an



advanced and thorough examination should be performed promptly if a new lesion is found.



**Figure 4: Microlithiasis. A. ultrasonography, B. histopathology cross-section (arrow sign shows calcification) (original figure A. With permission from radiologist and B. Made by the first author)**

### Orchitis and epididymo-orchitis

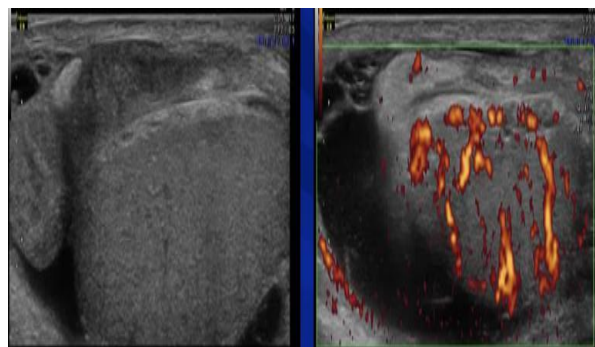
Infection is one of the most important factors in this field of study which mentioned in many researches. [46] Infection and inflammation of the male reproductive track can become one of the causes of male infertility. Epididymo-orchitis, either caused by local or systemic infection, or non communicable factor can affect the male reproductive function. [47] There is clear evidence that chronic inflammation in the testes can impair spermatogenesis and permanently disrupt sperm quality and concentration. Unfortunately, in most patients, the diagnosis has been made too late, due to the asymptomatic course of the disease, as well as no distinct clinical signs. Due to this reason, epidemiological data on orchitis and epididymo-orchitis is very scarce.

On the other hand, the result of testicular biopsy from infertile men showed a high prevalence of inflammation reaction. In chronic orchitis, a distinguished patron of focal and multifocal peritubular lymphocyte infiltration can be seen together with seminiferous tubules damage. These findings justify the concept that testicular inflammation induction is highly correlated with the autoimmune response which is mediated by T-cells.

The offender organism of orchitis and epididymo-orchitis most likely *Neisseria gonorrhoea* and *Chlamydia trachomatis*, as well as mumps virus. [48] In Chlamydial infection, the appearance of the lesions matches the appearance of a chronic-active inflammation lesion and granulomatous which represent various stages of inflammation in chlamydial infection in other mammals. [49, 50] Still unbeknownst yet the path of this infection whether this is an ascending infection or hematogenic spreading, although the appearance of the lesions showed the inclusion of tubules epithelial cells which related to interstitial granulomatous inflammation and macrophage

antigen phagocytosis followed by the damage of epithelial integrity. [51] Mild inflammation in intact seminiferous tubules – taking into account that seminiferous tubules are *immune-privileged tissue* – so, although there occurred complete spermatogenic cell degeneration, there is no possibility that interstitial orchitis would occur as long as the basal membrane of the tubules is still intact. Chlamydial infections in men can directly affect infertility by impairing sperm concentration, motility, morphology, and sperm DNA. [52]

Furthermore, although not a general lesion, testicular volume and Johnson's score for spermatogenesis can be significantly reduced. In conclusion, the inflammatory reaction, although asymptomatic, can still not be taken lightly as an underlying etiology or determining factor in male infertility. Because of that, the diagnosis of epididymo-orchitis, especially asymptomatic ones need better modalities, such as testicular ultrasonography, or even testicular biopsies. [53] Testicular ultrasonography in epididymo-orchitis shows enlargement and echo-textural heterogeneity appearance, hypo and hyperechoic epididymis accompanied by testicular enlargement. (Figure 5). In Doppler, there is also hyper vascularization, both in the testicle and in the epididymis. [54]



**Figure 5: Epididymo-orchitis (original figures with permission from radiologist)**

### Ejaculatory duct obstruction (EDO)

Ejaculation is an important process in male reproductive function. The path of ejaculation involves many reproductive organs as seen (Figure 6). One of the main causes of infertility is ejaculatory duct obstruction (EDO). EDO affects 1 to 5% of infertile men and can be congenital or acquired. [55] EDO may be caused by seminal vesicle stone, Mullerian/Wolffian duct cyst, post-operative or post-inflammatory cicatrix, or even functional obstruction. In acquired cases, EDO is mainly caused by infection, inflammation, calcification, and iatrogenic. [56]

EDO can be suspected if there are found: 1) azoospermia, 2) ejaculate volume < 2 ml with pH < 7.2 and the absence of fructose, 3) normal FSH and LH serum level, 4) normal testicular volume. The diagnosis of TRUS from EDO is

very useful in making the diagnosis of obstructive azoospermia and its clinical management decisions. TRUS in EDO appears as follows: 1) seminal vesicle dilatation (> 1.5 cm), 2) ejaculatory duct dilatation (> 2.3 mm), 3) cysts, calcification along the duct and 4) sperm in seminal vesicle secrete (Figure 7). Patients with congenital EDO or noninfectious EDO have a better prognosis compared to the ones with infection or complete EDO. Sperm parameters in the first group are much better than those in the next group after comprehensive management. [56, 57]

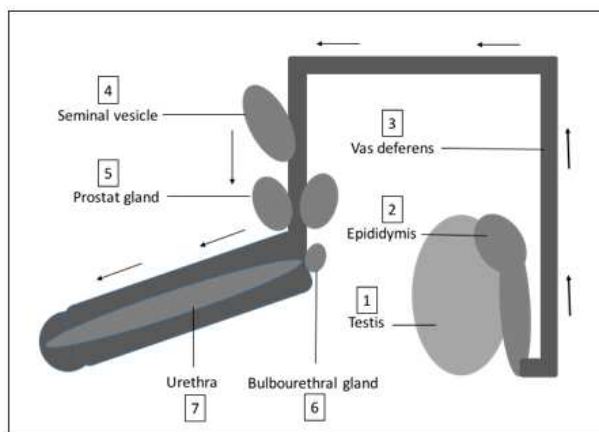


Figure 6: Ejaculatory pathway

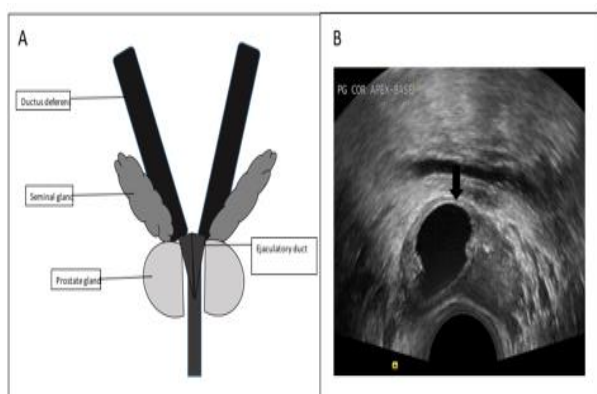


Figure 7: A. Ejaculatory duct, B. Ejaculatory duct obstruction by cyst (original figure A. Made by the first author, and B. With Radiologist's permission).

### Undescended testis

Undescended testis (UDT) or commonly referred to as cryptorchidism is defined as the absence of one or both testicles in the scrotum. UDT is the most common congenital abnormality in the male genitalia. [58, 59] UDT occurs in ~ 1% of infants over three months of age. [60] Etiology of UDT is still unknown, but is considered multifactorial due to endocrine factors, environment, genetic, anatomical, and mechanical, can be implemented in the development of these disorders. [61-64] Due to the declining pathway in the fetus, as seen in the picture, UDT can occur in several locations (Figure 8A). One of the

diagnostic modalities of UDT is through ultrasonography, such as inguinal UDT, as shown in the following figure (Figure 8B).

Bilateral UDT is more common in cases of infertility, compared to unilateral UDT. Research shows a decrease in sperm concentration in more than 50% of bilateral UDT men, and about 31% and 17% of unilateral UDT men. [17, 65, 66] This is due to reduced spermatogenesis in UDT. Under normal circumstances, gonadotropin and testosterone experienced an extreme increase in the third month of life. This physiological condition is the basis for the development of spermatogenic cells for optimal fertility status during growth. In the UDT, this condition is impaired so that the transformation of spermatogonia into adult dark cells (AD) (spermatogonia stem cells), is also disrupted. [67] Decreasing the number of AD cells causes the number of spermatocyte cells to decrease hence sperm concentration becomes low. [68]

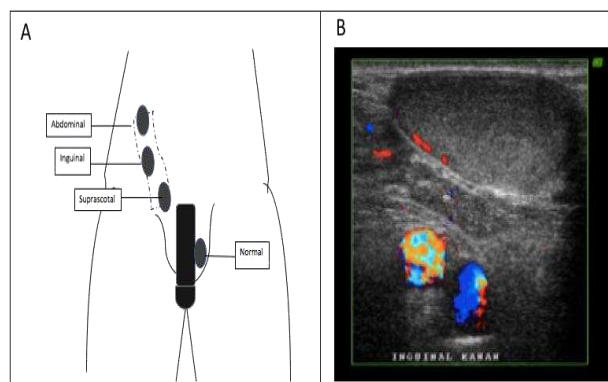


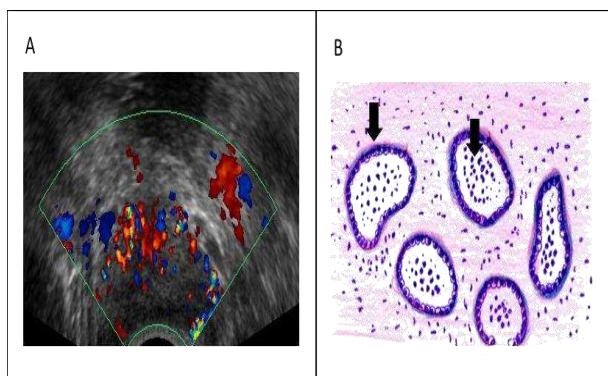
Figure 8: The undescended testicle A. Location, B. Ultrasonography (original figure A. Made by the first author and B. with radiologist's permission)

### Prostatitis

Male genital tract infections such as prostatitis, epididymis, and orchitis account for 12% of the etiology of male infertility. [69] The prevalence of prostatitis is about 14%. [70] According to the US National Institute of Health, National Institute of Diabetes and Digestive and Kidney Diseases (NIH-NIDDK), prostatitis is categorized into 4 categories: I (acute bacterial prostatitis), II (chronic bacterial prostatitis), III (chronic pelvic pain syndrome) and IV (asymptomatic inflammatory prostatitis). [71] Prostatic clinical manifestations vary, ranging from urinary disorders, pain in the genitorectal region, fever to infertility. Besides the presence of leukocytospermia, another modality for diagnosing prostatitis is ultrasonography, as shown in Figure 9A. When a biopsy of prostatitis is performed, an inflammatory reaction can be seen as shown in Figure 9B.

Complications of the prostate to infertility occur through various mechanisms such as 1) Prostate gland dysfunction, in the form of reduced fructose production, zinc to semen

volume [72]; 2) Antisperm antibodies (ASA) associated with the occurrence of non-bacterial prostatitis [73, 74] ; 3) Oxidative stress, where excessive ROS can cause sperm damage [75-77] and 4) Multiple pathogens such as *E. coli*, *C. trachomatis*, *mycoplasma*, *ureaplasma*, and *Enterococci* are reported to be associated with impaired motility, concentration and morphology, and sperm viability. [78-80] In addition to disorders of routine sperm analysis parameters, prostatitis can also increase sperm DNA fragmentation. [80]



**Figure 9: Prostatitis. A. ultrasonography, B. histopathology cross-section (arrow sign shows the presence of neutrophil cells in lumen and macrophages in stroma) (original Figure A with radiologist permission and B. Made by the first author)**

## CONCLUSION

Imaging of the male genital tract or male reproductive tract is very helpful in diagnosing andrological cases, especially in difficult cases whereas diagnosing could not be made only by anamnesis, physical examination, and routine seminal analysis. This study was performed to share information on the mechanism of sperm quality impairment that can cause infertility in andrological cases, such as varicocele, either directly caused by endocrine factors and testicular hypoxia or indirectly by formation ROS; microlithiasis, testicular atrophy, through seminiferous tubule damage which impair spermatogenesis; ejaculatory duct obstructions in which obstruct the ejaculatory path. Knowing the mechanism of sperm quality impairment accompanied by male genital tract imaging, we hope that clinicians can consider the best clinical management according to the more specific pathology.

## ACKNOWLEDGMENTS

The authors would like to thank Hibah Penelitian Unggulan Perguruan Tinggi (PUPT) 2019 at Universitas Indonesia for supporting this review article. We also

would like to thank Firda Asmaul Husna for helping in this review article.

## REFERENCES

- [1] Guttmacher AF. Factors affecting normal expectancy of conception. *J Am Med Assoc* 1956;161:855–60
- [2] te Velde ER, Eijkemans R and Habbema HDF. Variation in couple fecundity and time to pregnancy, an essential concept in human reproduction. *Lancet* 2000;355:1928–9
- [3] Bongaarts J. A method for the estimation of fecundability. *Demography* 1975;12:645–60.
- [4] Nasr NK, Eldakhkhny AM, Mohammed BM. Relation between sexual knowledge versus attitudes among female adolescents. *Pharmacophores*. 2018; 9(3):1-6.
- [5] Selem SM, Gonied AS, Mohamed HS, Elsebeiy F. Pregnancy Outcome of Nulliparous at Different Age Groups and Nursing Guidelines. *Int. J. Pharm. Res. Allied Sci*. 2018; 7(4):53-59.
- [6] World Health Organization. Towards more objectivity in diagnosis and management of male infertility. *Int J Androl (Suppl.)* 1987;7:1–53
- [7] Jose-Miller AB, Boyden JW and Frey KA. Infertility. *Am Fam Physician* 2007;75:849–56
- [8] Ammar T, Sidhu PS and Wilkins CJ. Male infertility: the role of imaging in diagnosis and management. *Br J Radiol* 2012;85:S59–S68.
- [9] Raza SA and Jhaveri KS. Imaging in male infertility. *Radiol Clin North Am* 2012;50: 1183 – 00.
- [10] Krausz C. Male infertility: pathogenesis and clinical diagnosis. *Best Pract Res Clin Endocrinol Metab* 2011;25:271–85
- [11] World Health Organization. WHO Manual for the Standardised Investigation and Diagnosis of the Infertile Couple. Cambridge, UK: Cambridge University Press; 2000.
- [12] Brugh VM and Lipshultz LI. Male factor infertility evaluation and management. *Med Clin N Am*. 2004;88:367-85
- [13] World Health Organization. WHO Laboratory Manual for the Examination and Processing of Human Semen. Geneva, Switzerland : WHO Press; 2010
- [14] Zini A and Boman JM. Varicocele: red flag or red herring? *Semin Reprod Med* 2009; 27:171–8.
- [15] Cayan S and Woodhous CRJ. The treatment of adolescents presenting with a varicocele. *BJU Internasional* 2007;100:744-7
- [16] Dubin L and Amelar RD. Varicocele size and results of varicolectomy in selected subfertile men with varicocele. *Fertil Steril* 1970;21:606 – 9.



- [17] Lee PA. Fertility after cryptorchidism: epidemiology and other outcome studies. *Urology* 2005;66(2):427–31.
- [18] Liguori G, Trombetta C, Garaffa G, Bucci S, Gattuccio I, Salame` L and Belgrano E. Color Doppler ultrasound investigation of varicocele. *World J Urol* 2004;22:378–81.
- [19] Jungwirth, A, Diemer, T, Dohle, GR, Giwercman, A, Kopa, Z, Tournaye H and Krausz C. Guidelines on male infertility, European Association of Urology, Arnhem, The Netherlands 2013.
- [20] Tijani KH, Oyende BO, Awosanya GO, Ojewola RW, Lawal AO and Yusuf AO. Scrotal abnormalities and infertility in west African men: A comparison of fertile and sub-fertile men using scrotal ultrasonography. *African Journal of Urology* 2014;20:18-3.
- [21] Telli O, Sarici H, Kabar M, Ozgur BC, Resorlu B and Bozkurt S. Does varicocelectomy affect DNA fragmentation in infertile patients? *Indian Journal of Urology*. 2015;31(2):116-9
- [22] Agarwal A, Hamada A and Esteves SC. Insight into oxidative stress in varicocele-associated male infertility: part 1. *Nat Rev Urol* 2012; 9:678-90.
- [23] Cho CL, Esteves SC and Agarwal A. Novel insight into the pathophysiology of varicocele and its association with reactive oxygen species and sperm DNA fragmentation. *Asian J Androl* 2016;18(2):186-93
- [24] Zhou T, Zhang W, Chen Q, Li L, Cao H, Xu CL, et al. Effect of varicocelectomy on testis volume and semen parameters in adolescents: a meta-analysis. *Asian J Androl* 2015;17(6):1012-6
- [25] Baazeem A, Belzile E, Ciampi A, Dohle G, Jarvi K, Salonia A, Weidner W and Zini A. Varicocele and male factor infertility treatment: a new meta-analysis and review of the role of varicocele repair. *Eur Urol* 2011;60:796 – 808.
- [26] Dilek ON. *Hernioplasty and testicular perfusion*. Springer Plus. 2014
- [27] Achdiat PA, Fadilla Y, Gunawan H and Suwarsa O. Testicular atrophy and its clinical manifestations in a patient released from leprosy treatment. *Lepr Rev* 2018;89:83–6
- [28] Sidhu PS. Diseases of the testis and epididymis. In: Baxter GM, Sidhu PS, editors. , eds. *Ultrasound of the urogenital system*. Stuttgart, Germany: Thieme; 2006; 153–80
- [29] Leal AMO and Foss NT. Endocrine dysfunction in leprosy. *Eur J Clin Microbiol Infect Dis* 2009; 28: 1–7.
- [30] Saporta L and Yuksel A. Androgenic status in patients with lepromatous leprosy. *BJU Int* 1994; 74: 221–4.
- [31] Andrade LO, Oliveira MF, Franca LS, Souza AF, Andrade CS and Jesus HB. Hypogonadism in leprosy males. *R C Med Biol* 2012; 11: 60-3
- [32] Doherty FJ, Mullins TL, Sant GR, Drinkwater MA and Ucci AA Jr. Testicular microlithiasis. A unique sonographic appearance. *J Ultrasound Med* 1987;6:389-92
- [33] Kim B and Winter Tc Ryu. Testicular microlithiasis: Clinical significance and review of the literature. *Radiology* 2003;13:2567-76
- [34] Middleton WD, Teefey SA and Santillan CS. Testicular microlithiasis: prospective analysis of prevalence and associated tumor. *Radiology* 2002;224:425-8
- [35] McLachlan RI, Rjpert-De Meyts R, Hoei-Hansen CE, de Kretser DM and Skakkebaek NE. *Hum Reprod* 2007;22:2-16
- [36] Nistal M, Gonzalez-Peramato P, Regadera J, Srrano A, Tarin V, et al. Primary testicular lesions are associated with testicular germ cell tumors of adult ment. *Am J Surg Pathol* 2006;30:1260-8.
- [37] Costabile RA. How worrisome is testicular microlithiasis? *Curr Opin Urol* 2007;17:419-23
- [38] Pedersen MR, Bartlett EC, Rafaelsen SR, Osther PJ, Vedsted P, Sellars ME, et al. Testicular microlithiasis is associated with ethnicity and socioeconomic status. *Acta Radiologica Open* 2017;6(8):1-5
- [39] Goede J, Hack WW, van der Voort-Doedens LM, Sijstermans K and Pierik FH. Prevalence of testicular microlithiasis in asymptomatic males 0 to 19 years old. *J Urol* 2009;182:1516-20
- [40] Derogee M, Bevers DR, Prins HJ, Jonges TG, Elbers FH, et al. Testicular microlithiasis, a premalignant condition: prevalence, histopathologic findings and relation to testicular tumor. *Urology* 2001;57:1133-7
- [41] de Gouveia Brazao CA, Pierik FH, Oosterhuis JW, Dohle GR, Looijenga LH, et al. Bilateral testicular microlithiasis predicts the presence of the precursor of testicular germ cell tumors in subfertile men. *J Urol* 2004;171:158-60.
- [42] Hoei-Hansen CE, Sommer P, Meyts ER and Skakkebaek NE. A rare diagnosis: testicular dysgenesis with carcinoma in situ detected in a patient with ultrasonic microlithiasis. *Asian J Androl* 2005;7:445-7.
- [43] Vachon L, Fareau GE, Wilson MG and Chan LS. Testicular microlithiasis in patients with Down syndrome. *J Pediatr* 2006;149:233-6.
- [44] Jequier AM, Phillips N and Yovich JL. Testicular microlithiasis among infertile men: A reason for concern? *Andrology and Gynecology: Current Research* 2014;2(2):1-5



- [45] Renshaw AA. Testicular calcifications: Incidence, histology and proposed pathological criteria for testicular microlithiasis. *The Journal of Urology* 1998;160(5):1625-8
- [46] Usman A, Ming LC, Khan TM. Drug-Resistant Sexually Transmitted Infections in Southeast Asia: Regional Challenges to Control. *Arch. Pharma. Pract.* 2019;10(1):1-4.
- [47] Schuppe HC, Pilatz A, Hossain H, Meinhardt A, Bergmann M, Haidl G, et al. Orchitis and male infertility. *Urologe A* 2010;49:629-35
- [48] Subramanyan BR, Horri SC and Hilton S. Diffuse testicular disease: sonographic features and significance. *AJR Am J Roentgenol* 1985;145:1221-4
- [49] Jaskowski L, Sadowski JM, Hoffmannwozniak K, Wieczor H and Truszczynski M. Experimental chlamydiosis in bulls: effects of unilateral intra-testicular inoculation. *Bulletin of the Veterinary Institute in Pulawy* 1979;23:14-20.
- [50] Storz J, Carroll EJ, Stephenson EH, Ball L and Eugster AK. Urogenital infection and seminal excretion after inoculation of bulls and rams with *Chlamydiae*. *Am J Vet Res* 1976; 37:517-20
- [51] Johnston SD, Deif HH, McKinnon A, Theilemann P, Griffith JE, and Higgins DP. Orchitis and Epididymitis in Koalas (*Phascolarctos cinereus*) Infected with *Chlamydia pecorum*. *Veterinary Pathology* 2015;52(6):1254-7
- [52] Cunningham KA and Beagley KW. Male genital tract chlamydial infection: implications for pathology and infertility. *Biol Reprod* 2008;79:180-9.
- [53] Schuppe HC, Meinhardt A, Allam JP, Bergmann M, Weidner W and Haidl G. Chronic orchitis: a neglected cause of male infertility? *Andrologia* 2008;40(2):84-91
- [54] Dogra VS, Gottlieb RH, Oka M and Rubins DJ. Sonography of the scrotum. *Radiology* 2003;227:18-36
- [55] Singh R, Hamada AJ, Bukavina L and Agarwal A. Physical deformities relevant to male infertility. *Nature* 2012; 9:156-4
- [56] Fisch H, Kang YM, Johnson CW and Goluboff ET. Ejaculatory duct obstruction. *Current opinion in urology* 2002;12:509-15
- [57] El-Assmy A, El-Tholoth H, Abouelkheir RT and Abou-El-Ghar ME. Transurethral resection of ejaculatory duct in infertile men: outcome and predictors of success. *Int Urol Nepprol* 2012;44(6):1623-30
- [58] Serrano T, Chevrier C, Multigner L, Cordier S and Jégou B. International geographic correlation study of the prevalence of disorders of male reproductive health. *Hum Reprod* 2013;28(7):1974-86.
- [59] Wood HM and Elder JS. Cryptorchidism and testicular cancer: separating fact from fiction. *J Urol* 2009;181(2):452-61.
- [60] Brucker-Davis F, Pointis G, Chevallier D and Fenichel P. Update on cryptorchidism: endocrine, environmental and therapeutic aspects. *J Endocrinol Invest* 2003;26(6):575-87.
- [61] Mathers MJ, Sperling H, Rübber H and Roth S. The undescended testis: diagnosis, treatment and long-term sequelae. *Dtsch Arztebl Int* 2009;106(33):527-32.
- [62] Ferlin A, Zuccarello D, Garolla A, Selice R and Foresta C. Hormonal and genetic control of testicular descent. *Reprod Biomed Online* 2007;15(6):659-65.
- [63] Robin G, Boitrelle F, Marcelli F, et al. Cryptorchidism: from physiopathology to infertility. *Gynecol Obstet Fertil* 2010;38(10):588-99.
- [64] de Sanctis C, Lala R, Canavese F. Cryptorchidism, *La Pediatria Medicae Chirurgica: Medical and Surgical Pediatrics* 1995;17(1):23-8.
- [65] Cobellis G, Noviello C, Nino F, et al. Spermatogenesis and cryptorchidism. *Front Endocrinol (Lausanne)* 2014;5:63.
- [66] Kobayashi H, Nagao K and Nakajima K. Therapeutic Advances in the Field of Male Infertility: Stem Cell Research. *Advanced Studies in Medical Sciences* 2013;1(1):39-54.
- [67] Biers SM and Malone PS. A critical appraisal of the evidence for improved fertility indices in undescended testes after gonadotrophin-releasing hormone therapy and orchidopexy. *J Purol* 2010;6(3):239-46.
- [68] Fawzy F, Hussein A, Eid Mostafa, Kashash AME and Salem HK. Crptorchidism and fertility. *Clin Med insights Reprod Health* 2015;9:39-43.
- [69] Dohle, G.R., 2003. Inflammatory-associated obstructions of the male reproductive tract. *Andrologia* 35, 321-4.
- [70] Mehik, A., Hellstrom, P., Lukkarinen, O., Sarpola, A and Jarvelin, M., 2000. Epidemiology of prostatitis in Finnish men: a population-based cross-sectional study. *BJU Int* 86, 443-8.
- [71] Krieger, J.N., Nyberg Jr., L and Nickel, J.C., 1999. NIH consensus definition and classification of prostatitis. *JAMA* 282, 236-7.
- [72] Marconi, M., Pilatz, A., Wagenlehner, F., Diemer, T and Weidner, W. Impact of infection on the secretory capacity of the male accessory glands. *Int. Braz. J. Urol* 2009;35:299-308

- [73] Jarow, JP., Kirkland Jr., J.A and Assimos, D.G. Association of antisperm antibodies with chronic nonbacterial prostatitis. *Urology* 1990;36: 154–6.
- [74] Hoover, P and Naz R.K., 2012. Do men with prostate abnormalities (prostatitis/benign prostatic hyperplasia/prostate cancer) develop immunity to spermatozoa or seminal plasma? *Int. J. Androl* 35, 608–15.
- [75] Kullisaar, T., Turk, S., Punab, M and Mandar, R. Oxidative stress – cause or consequence of male genital tract disorders? *Prostate* 2012;72:977–83
- [76] Pasqualotto, F.F., Sharma, R.K., Potts, J.M., Nelson, D.R., Thomas, A.J and Agarwal A., Seminal oxidative stress in patients with chronic prostatitis. *Urology* 2000;55: 881–5.
- [77] Ochsendorf, F.R. Infections in the male genital tract and reactive oxygen species. *Hum. Reprod. Update* 1999;5:399–420.
- [78] Schulz, M., Sanchez, R., Soto, L., Risopatron, J and Villegas, J. Effect of *Escherichia coli* and its soluble factors on mitochondrial membrane potential, phosphatidylserine translocation, viability, and motility of human spermatozoa. *Fertil Steril* 2010; 94: 619–23.
- [79] Mazzoli, S., Cai, T., Addonisio, P., Bechi, A., Mondaini, N and Bartoletti, R., 2010. Chlamydia trachomatis infection is related to poor semen quality in young prostatitis patients. *Eur. Urol* 2010;57:708–14.
- [80] Alshahrani S, McGill J and Agarwal A. Prostatitis and male infertility. *J Reprod Immunol.* 2013; 7:1-7.