

# Laparoscopic treatment of pelvic pain associated with minimal and mild endometriosis with use of the Helica Thermal Coagulator

Luciano G. Nardo, M.D., Magdy Moustafa, M.D., and D.W. Gareth Beynon, F.R.C.O.G.

Department of Obstetrics and Gynaecology, Frimley Park Hospital, Camberley, Surrey, United Kingdom

**Objective:** To investigate the clinical efficacy and safety of Helica Thermal Coagulator (TC) in the treatment of pelvic pain associated with minimal (stage I) and mild (stage II) endometriosis.

**Design:** A clinical observational study.

**Setting:** A referral center for laparoscopic treatment of endometriosis.

**Patient(s):** Eighty-one women with pelvic pain symptoms associated with minimal and mild endometriosis diagnosed at laparoscopy.

**Intervention(s):** Helica TC to treat endometriotic lesions. The revised American Fertility Society (rAFS) classification was used to stage endometriosis. Pain symptoms and patient satisfaction were assessed subjectively at 3 and 6 months follow-up.

**Main Outcome Measure(s):** Improvement or relief of pelvic pain symptoms, and intra- or postoperative complications.

**Result(s):** A total of 79 women completed the study to 6 months follow-up. At 3 months, 59 (74.7%) women reported resolution and satisfactory improvement of symptoms, whereas 20 (25.3%) women continued to experience painful symptoms. At 6 months, 69 (87.4%) women reported resolution and satisfactory improvement of symptoms, whereas 9 (11.4%) women reported no changes and 1 (1.2%) woman experienced worsening symptoms. No significant differences were found between minimal and mild disease. No side effects or surgical complications occurred.

**Conclusion(s):** Meaningful improvements and relief in clinical symptoms can be obtained with conservative laparoscopic surgery. Helica TC is a simple, effective, and safe device for the treatment of pelvic pain in women with stages I and II endometriosis. This approach requires further evaluation as part of randomized controlled trials. (Fertil Steril® 2005;83:735–8. ©2005 by American Society for Reproductive Medicine.)

**Key Words:** Endometriosis, rAFS classification, pelvic pain, Helica TC

Endometriosis is one of the most common and debilitating gynecological conditions affecting women during their reproductive lives. It is variable in both its clinical manifestation and surgical appearance, often with poor correlation between the two. Overall, endometriosis is found in up to 70% of diagnostic laparoscopies for pelvic pain and more than 80% of cases with pelvic pain and subfertility (1). Apart from noncyclical pelvic pain, the symptoms of endometriosis may also include dysmenorrhea and deep dyspareunia (2).

A large body of evidence showed that endometriosis is a dynamic benign disease, and the majority of women are not going to improve if untreated (3, 4). However, among the scientific community, there is consensus that treatment of endometriosis and its symptoms has to be closely linked to and dependent upon women's wishes.

Whether surgical management is more effective than medical management is still a matter of much scientific debate. Therefore, clinicians are increasingly faced with

the dilemma of management of endometriosis in otherwise healthy women. Recently, a well-structured review assessing the current evidence to compare laparoscopic surgery and medical therapy reported that the former approach represents a beneficial treatment and is less likely to lead to early recurrence of the disease (5). Nevertheless, although the advent of minimal access surgery in gynecology has opened a new avenue in the conservative treatment of endometriosis-related symptoms, there is some debate regarding the optimal technique and mode of ablation of endometriotic disease.

In 1993, Maurice Howieson and colleagues, at the University of Strathclyde in Glasgow, developed the Helica Thermal Coagulator (TC) system with the specific task of solving the problems associated with soft tissue coagulation. Using a combination of low volume helium gas and very low electrical power (2–8 watts), the Helica TC allows cauterization to the precise area of tissue in a highly controllable and noncontact mode, avoiding oxidization and carbonization. The depth of penetration is easily controlled by the power setting and the distance of the probe from the tissue (6).

Received September 19, 2003; revised and accepted July 26, 2004.  
Reprint requests: Luciano G. Nardo, M.D., St. Mary's Hospital, Whitworth Park, Manchester M13 0JH, United Kingdom (FAX: +44-0161-224-0957; E-mail: luciano.nardo@cmmc.nhs.uk).

The aim of this observational study was to investigate the clinical efficacy and safety of Helica TC in the treatment of pelvic pain associated with minimal and mild endometriosis.

## MATERIALS AND METHODS

Eighty-one women (mean age 32 years old; range 19–41) complaining of pain symptoms suggestive of pelvic endometriosis, who were referred to the gynecological outpatient clinic between December 2001 and January 2003, were included in the study. Infertility was considered separately. The women had not received any treatment for endometriosis during the previous 6 months. All women were advised to undergo a diagnostic laparoscopy and further laparoscopic surgery as required. Counseling regarding the potential risks of laparoscopy was offered, and a written informed consent was taken. Institutional Review Board (IRB) approval was not required because diagnostic and surgical procedures that were in keeping with the department's usual clinical practice were recommended to the patients. The use of Helica TC was approved by the National Health Service Trust Research and Development Committee.

A laparoscopy was performed with the use of a triple-puncture technique. Where indicated, serosanguinous fluid was aspirated from the pouch of Douglas. A thorough examination of the pelvic area was performed, and the site of any endometriotic lesion was noted. The relationship to the urinary tract, bowel, and vessels was also identified. Endometriosis was staged as minimal (stage I) or mild (stage II) according to the revised American Fertility Society (rAFS) classification (7). Women with pelvic pathology other than endometriosis and those with endometriotic cysts were excluded from this analysis. Laparoscopic treatment included cauterization/ablation of all visible endometriotic implants with the Helica TC (Helica Instruments Ltd; Riccarton, Edinburgh, United Kingdom) and adhesiolysis using blunt and sharp dissection. At the end of the operation, the peritoneal cavity was irrigated until it was devoid of debris, and 400 mL of Hartmann's solution was instilled.

No medical treatment for endometriosis was prescribed during the follow-up period, and thereafter, gonadotropin-releasing hormone (GnRH)-analogue (GnRH-a) (Zoladex®; Astra Zeneca, Bedfordshire, United Kingdom) was given if symptoms persisted. Women were followed up expectantly at 3 and 6 months postoperatively. To evaluate variations in symptoms, women were asked to give a subjective assessment of the presence and severity of noncyclical pelvic pain, dysmenorrhea and deep dyspareunia. Efficacy was based on variations in symptoms and patient satisfaction after Helica TC. In accordance with these parameters, the treatment outcome was graded as follows: symptom relief/very satisfied, symptom improvement/satisfied, and no symptom changes/dissatisfied.

All collected data were analyzed with the use of descriptive statistics suitable for an observational study. Data from

the different stages of endometriosis were compared with the use of the  $\chi^2$  test for trend (qualitative data).

## RESULTS

Out of the 81 women who were recruited, 79 completed the study to 6 months follow-up, while the remaining 2 women were lost to follow-up and excluded from the final analysis. Demographic characteristics of the study population (n = 79) are reported in Table 1. The most common symptom was noncyclical pelvic pain (93.7%), whereas dysmenorrhea and deep dyspareunia accounted for 48% and 74.7%, respectively. Overall, 35 (44.3%) women had stage I disease and 44 (55.7%) women had stage II disease as noted at the time of diagnostic laparoscopy. Filmy adhesions between the adnexa and ipsilateral pelvic sidewall were found in 12 (15.2%) women. In all cases, adhesions were dissected and anatomy restored at the time of diagnosis.

At 3 months follow-up, 39 (49.4%) women were asymptomatic and 20 (25.3%) experienced significant symptom improvement, whereas 20 (25.3%) women reported little or no changes. At 6 months follow-up, 45 (57%) and 24 (30.4%) women reported satisfactory symptom relief and improvement, respectively, while 9 (11.4%) women reported no variations and 1 (1.2%) woman experienced worsening symptoms. Variation of symptoms and patient satisfaction at 3 and 6 months after the Helica TC are listed in Table 2. Of the 10 women whose pain symptoms persisted after laparoscopic treatment, 6 underwent total abdominal hysterectomy and bilateral salpingo-oophorectomy (i.e., pelvic clearance), while the remaining 4 women received GnRH-a and add-back therapy for 6 consecutive months.

**TABLE 1**

### Study population demographics.

No. of women	79
Mean age (y) (range)	32 (19–41)
Parity	
Nulliparous	46
Multiparous	30
Revised AFS classification	
No. of women with stage I disease (%)	35 (44.3%)
No. of women with stage II disease (%)	44 (55.7%)
Endometriosis surrounding bladder	21 (26.6%)
Endometriosis surrounding ureters	9 (11.4%)
Endometriosis surrounding bowel	4 (5.1%)
Symptoms	
Noncyclical pelvic pain	93.7%
Deep dyspareunia	74.7%
Dysmenorrhea	48.0%

Note: AFS = American Fertility Society.

Nardo. Helica TC for early stages of endometriosis. Fertil Steril 2005.

**TABLE 2****Variation of symptoms and patient satisfaction at 3 and 6 months follow-up.**

Symptom variation/ patient satisfaction	Follow-up period	
	3 months	6 months
Symptom relief/very satisfied	39 (49.4%)	45 (57.0%)
Symptom improvement/satisfied	20 (25.3%)	24 (30.4%)
No symptom changes/dissatisfied	20 (25.3%)	9 (11.4%)
Symptom worsening/very dissatisfied	—	1 (1.2%)

Nardo. Helica TC for early stages of endometriosis. Fertil Steril 2005.

When analyzing the successful outcome with respect to the rAFS classification, no statistically significant difference was found between minimal and mild endometriosis (Fig. 1). At 3 months follow-up, 18 (51.4%) of 35 women with stage I disease and 21 (47.7%) of 44 women with stage II disease were asymptomatic. Similarly, at 6 months follow-up, 20 (57.1%) of 35 women with stage I disease and 25 (56.8%) of 44 women with stage II disease were asymptomatic.

Overall, no surgical complications were encountered, although tissue surrounding the bladder, ureters, and bowel was extensively treated as necessary. The majority of women who underwent treatment by the Helica TC remained in the hospital overnight, while others were discharged home on the same day.

## DISCUSSION

This study showed that combination of helium gas and very low electrical power is a versatile, effective, and safe laparoscopic approach for treating painful symptoms in women with minimal and mild pelvic endometriosis. The majority of women reported symptom improvement without experiencing adverse effects or complications. Collectively, 74.7% and 87.4% of women reported satisfactory symptom relief and improvement at 3 and 6 months, respectively.

As yet, there is no widely formalized pain scoring system for pelvic pain associated with endometriosis. It was reported that endometriosis stage per se is not related consistently to frequency and severity of pelvic pain symptoms (8). In accordance with these data, we were unable to demonstrate a positive correlation between stage and symptoms of endometriosis after the use of the Helica TC. As presented in Figure 1, the success rate, measured as relief of symptoms and patient satisfaction, was similar for stage I and stage II disease during the follow-up period.

Without a doubt, the treatment for endometriosis and its symptoms continues to be an enigmatic issue. It is often

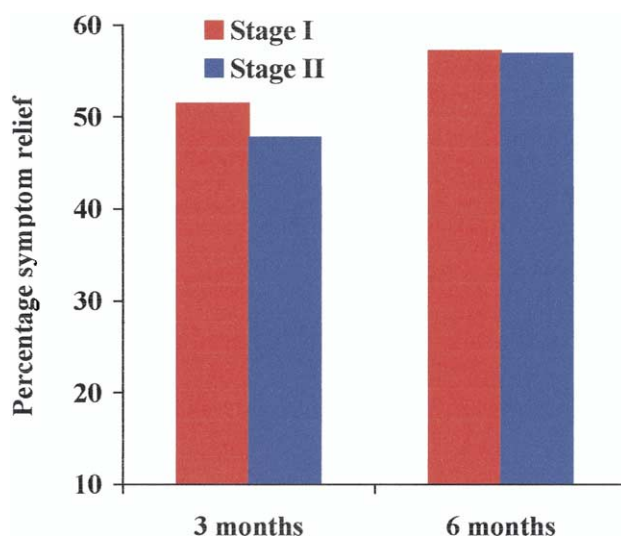
difficult to evaluate the efficacy of treatments because chronic pelvic pain may have different organic components and may be influenced by external factors such as personality and psychosocial background (9, 10). Medical therapy has not been shown to eradicate this disease completely, and surgery is often required to definitively diagnose and treat endometriosis. A number of reports have demonstrated that the cumulative recurrence rate of endometriotic implants and symptoms after medical management appears to be significantly higher compared with surgical excision or ablation of the disease (4, 11–14). The reason for the poorer results after medical treatment may well be because it only controls endometriosis temporarily and symptoms will recur once hormonal suppression is stopped (15). Alternatively, postoperative treatment with GnRH-a significantly prolongs the pain-free interval after conservative surgery for symptomatic endometriosis (16). Recently, the clinical efficacy of laparoscopic surgery as treatment of choice for painful symptoms and recurrence of endometriosis has been published (17, 18).

Fedele et al. (19) demonstrated that a placebo effect could improve dysmenorrhea in up to 30% of women treated; however, this effect lasted no longer than 3 months. Of note, there may also be some mechanism whereby a laparoscopy alone results in temporary improvement of pelvic pain symptoms.

To our knowledge, this is the first report in the literature to assess the efficacy and safety of this power-controlled device to treat pelvic endometriosis-associated symptoms. In this respect, studies comparing the success rate following this conservative approach vs. others, either medical or surgical,

**FIGURE 1**

Distribution of women with symptom relief/very satisfied (i.e., asymptomatic) related to stage of endometriosis (rAFS classification).



Nardo. Helica TC for early stages of endometriosis. Fertil Steril 2005.

cannot be considered yet. However, it is interesting to note that the overall results after the Helica TC appear to be similar to those reported after CO<sub>2</sub> laser vaporization (20), especially for early stages of the disease. These investigators (20), unlike the present study, did not mention whether they also used CO<sub>2</sub> laser to vaporize visible endometriotic implants around the bladder, ureters, and bowel. Although we can only conclude that the Helica TC appears to be extremely safe, and the risk of injury to other anatomical structures is likely to be very small, the limits of the present study have to be recognized.

With regard to the failure rate reported in this observational study, it is plausible that all those women (n = 10, 12.6%) who failed to benefit from treatment at 6 months follow-up might have had more severe disease. In fact, there is evidence that women who experience endometriosis-related pelvic pain may have larger lesions that infiltrate deeper (1) or, alternatively, active nonpigmented subtle lesions (21, 22) that are not visualized at laparoscopy. Therefore, biopsies of the peritoneum to confirm the diagnosis and plan further management would represent a sensible approach that may be considered in women with endometriosis-associated symptoms but without evidence of disease at laparoscopy.

In conclusion, analysis of this cohort of women, whose gynecological history was complicated by stage I and II endometriosis only, suggests that the Helica TC is an effective approach in inducing destruction of superficial endometriotic deposits and reducing subjective symptoms. Furthermore, its results are safe, and it enables the treatment of endometriosis that surrounds crucial structures without causing complications. Due to the study design and the placebo effect of laparoscopy, the present study lacks the power to demonstrate data conclusively. Properly designed randomized, controlled trials (i.e., Level 1 evidence) and a longer follow-up period have to be undertaken to further investigate the role of the Helica TC in the treatment of pelvic endometriosis and related symptoms.

*Acknowledgment:* We thank Mrs. Alison Kinch, Frimley Park Hospital, Surrey, United Kingdom, for her help in collecting data for this study.

## REFERENCES

1. Koninckx PR, Meuleman C, Demeyere S, Lesaffre E, Cornillie FJ. Suggestive evidence that pelvic endometriosis is a progressive disease, whereas deeply infiltrating endometriosis is associated with pelvic pain. *Fertil Steril* 1991;55:759–65.
2. Garry R, Clayton R, Hawe J. The effect of endometriosis and its radical laparoscopic excision on quality of life indicators. *Br J Obstet Gynaecol* 2000;107:44–54.

3. Mahmood TA, Templeton A. The impact of treatment on the natural history of endometriosis. *Hum Reprod* 1990;5:965–70.
4. Jones KD, Haines P, Sutton CJG. Long-term follow-up of a controlled trial of laser laparoscopy for pelvic pain. *JSLs* 2001;5:111–5.
5. Jacobson TZ, Barlow DH, Garry R, Koninckx P. Laparoscopic surgery for pelvic pain associated with endometriosis (Cochrane Review). In: *The Cochrane Library*, Issue 3, 2003.
6. Sutton C. Power sources in endoscopic surgery. *Curr Opin Obstet Gynecol* 1995;7:248–56.
7. The American Fertility Society. Revised American Fertility Society classification of endometriosis: 1985. *Fertil Steril* 1985;43:351–2.
8. Vercellini P, Trespidi L, De Giorgi O, Cortesi I, Parazzini F, Crosignani PG. Endometriosis and pelvic pain: relation to disease stage and localization. *Fertil Steril* 1996;65:299–304.
9. Gomibuchi H, Taketani Y, Doi M. Is personality involved in the expression of dysmenorrhoea in patients with endometriosis? *Am J Obstet Gynecol* 1993;161:871–6.
10. Reiter RC. Evidence-based management of chronic pelvic pain. *Clin Obstet Gynecol* 1998;41:422–35.
11. Redwine DB. Conservative laparoscopic excision of endometriosis by sharp dissection: life table analysis of reoperation and persistent or recurrent disease. *Fertil Steril* 1991;56:628–34.
12. Waller KG, Shaw RW. Gonadotrophin-releasing hormone analogues for the treatment of endometriosis: long-term follow-up. *Fertil Steril* 1993;59:511–5.
13. Hornstein MD, Yuzpe AA, Burry KA, Heinrichs L, Buttram VL, Orwoll ES. Prospective randomized double-blind trial of 3 versus 6 months of nafarelin therapy for endometriosis associated pelvic pain. *Fertil Steril* 1995;63:955–62.
14. McParland P, Halligan AWF, Taylor DJ, Naftalin NJ. Laparoscopic laser treatment for endometriosis. *Gynecol Obstet Invest* 1997;44:38–40.
15. Miller JD, Shaw RW, Casper RF, Rock JA, Thomas EJ, Dmowski WP, et al. Historical prospective cohort study of the recurrence of pain after discontinuation of treatment with danazol or a gonadotropin-releasing hormone agonist. *Fertil Steril* 1998;70:293–6.
16. Vercellini P, Crosignani PG, Fadini R, Radici E, Belloni C, Sismondi P. A gonadotrophin-releasing hormone agonist compared with expectant management after conservative surgery for symptomatic endometriosis. *Br J Obstet Gynaecol* 1999;106:672–7.
17. Farquhar C, Sutton CJG. The evidence for the management of endometriosis. *Curr Opin Obstet Gynaecol* 1998;10:321–32.
18. Sutton CJG, Jones KD. Laser laparoscopy for endometriosis and endometriotic cysts. *Surg Endosc* 2002;16:1513–7.
19. Fedele L, Marchini M, Acaia B, Garagiola U, Tiengo M. Dynamics and significance of placebo response in primary dysmenorrhoea. *Pain* 1989;36:43–7.
20. Sutton CJG, Ewen SP, Whitelaw N, Haines P. Prospective, randomised, double-blind, controlled trial of laser laparoscopy in the treatment of pelvic pain associated with minimal, mild, and moderate endometriosis. *Fertil Steril* 1994;62:696–700.
21. Murphy AA, Green WR, Bobbie D, de la Cruz ZC, Rock JA. Unsuspected endometriosis documented by scanning electron microscopy in visually normal peritoneum. *Fertil Steril* 1986;46:552–4.
22. Nisolle M, Casanas-Roux F, Donnez J. Peritoneal endometriosis: evaluation of typical and subtle lesions. In: Donnez J, Nisolle M, eds. *An atlas of operative laparoscopy and hysteroscopy*. New York: The Parthenon Publishing Group Inc., 2001:49–62.